

GENERAL SURGERY

Dr. S. Gallinger
Gordon Buduhan and Sam Minor, editors
Dana McKay, associate editor

PREOPERATIVE PREPARATION.....	2	LIVER.....	30
SURGICAL COMPLICATIONS.....	2	Liver Cysts	
Wound Complications		Liver Abscesses	
Urinary and Renal		Neoplasms	
Respiratory		Portal Hypertension	
Cardiac		Liver Transplantation	
Paralytic Ileus		BILIARY TRACT.....	34
Post-Operative Delirium		Cholelithiasis	
Post-Operative Fever		Biliary Colic	
Intra-abdominal Abscess		Acute Cholecystitis	
ACUTE ABDOMEN.....	6	Complications of Cholecystectomy	
Specific "Signs" on Physical Examination		Acalculous Cholecystitis	
Evaluation		Gallstone Pancreatitis	
ESOPHAGUS.....	9	Gallstone Ileus	
Hiatus Hernia		Diagnostic Evaluation of Biliary Tree	
Structural Lesions		Choledocholithiasis	
Motility Disorders		Acute Cholangitis	
Other Disorders		Carcinoma of the Bile Duct	
Esophageal Perforation		Jaundice	
Esophageal Carcinoma		PANCREAS.....	39
STOMACH AND DUODENUM.....	12	Acute Pancreatitis	
Gastric Ulcers		Chronic Pancreatitis	
Duodenal Ulcers		Pancreatic Cancer	
Gastric Carcinoma		SPLEEN.....	41
Complications of Gastric Surgery		Hypersplenism	
BOWEL OBSTRUCTION.....	15	Splenectomy	
Small Bowel Obstruction		FISTULA.....	42
Large Bowel Obstruction		BREAST.....	42
SMALL INTESTINE.....	18	Fibrocystic Disease	
Tumours of Small Intestine		Fibroadenoma	
Meckel's Diverticulum		Fat Necrosis	
APPENDIX.....	19	Papilloma	
Appendicitis		Differential Diagnosis of Nipple Discharge	
Tumours of the Appendix		Mastitis	
INFLAMMATORY BOWEL DISEASE.....	20	Breast Cancer	
Crohn's Disease		Male Breast Lumps	
Ulcerative Colitis		THYROID.....	47
LARGE INTESTINE.....	21	VASCULAR - ARTERIAL DISEASES.....	47
Diverticular Disease		Arterial Insufficiency	
Angiodysplasia		Chronic Ischemia	
Volvulus		Critical Ischemia	
Colorectal Polyps		Acute Limb Ischemia	
Colorectal Carcinoma		Abdominal Aortic Aneurysm	
Ileostomies and Colostomies		Ruptured Abdominal Aortic Aneurysm	
ANORECTUM.....	26	Aortic Dissection	
Hemorrhoids		VASCULAR - VENOUS DISEASES.....	51
Anal Fissures		Deep Vein Thrombosis	
Anorectal Abscess		Varicose Veins	
Perirectal Suppuration		Superficial Thrombophlebitis	
Fistula-in-ano		Chronic Deep Vein Insufficiency	
Pilonidal Disease		HIV AND GENERAL SURGERY.....	54
Rectal Prolapse		Susceptible Organs in GI Tract	
Anal Neoplasms		Unusual Malignancies	
HERNIA.....	28	Indications for Surgery in HIV Positive Patients	
		Nosocomial Transmission	
		CANCER GENETICS.....	56

- consent
- consults - anesthesia, medicine, cardiology, etc...
- components - blood components: group and screen or crossmatch depending on procedure
- diet - NPO after midnight
- AAT, vital signs routine
- IV - balanced crystalloid at maintenance rate (4:2:1 rule)
 - Ringer's lactate or normal saline
- investigations
 - CBC, U/A, lytes, BUN, creatinine
 - INR/PT, PTT with history of bleeding disorder
 - ABGs if predisposed to respiratory insufficiency
 - CXR (PA and lateral) unless < 35 years old or previously abnormal within past 6 months
 - ECG > 35 years old or as indicated by past cardiac history
- drugs (including oxygen)
 - patient's regular meds including prednisone - consider pre-op boost
 - prophylactic antibiotics (e.g. cefazolin) if
 - clean/contaminated cases (i.e. GI/GU/respiratory tracts are entered)
 - contaminated cases - trauma
 - insertion of foreign material (e.g. vascular grafts)
 - high risk patients (e.g. prosthetic heart valves, rheumatic heart disease)
 - bowel prep (decreases bacterial population e.g. Ancef, Cipro, Flagyl)
- drains
 - nasogastric tube
 - indications: gastric decompression, analysis of gastric contents, irrigation/dilution of gastric contents, feeding (only if necessary --> due to risk of aspiration, naso-jejunal tube preferable)
 - contraindications: absolute - obstruction of nasal passages due to trauma, suspected basilar skull fracture, relative - maxillofacial fractures; for these may use oral-gastric tube
 - Foley catheter
 - indications: to accurately monitor urine output, decompression of bladder, relieve obstruction
 - contraindications: suspected disruption of the urethra, difficult insertion of catheter

SURGICAL COMPLICATIONS

WOUND COMPLICATIONS

Wound Infection

- wounds become infected in the OR while open
- risk of infection depends on type of procedure
 - clean (excisional biopsy) - 3%
 - clean-contaminated (GI, biliary) - 5-15%
 - contaminated (surgery on unprepped bowel, emergency surgery for GI bleeds/perforation) - 15-40%
 - dirty (penetrating trauma) - 40%
- most common etiologic agent = *S. aureus*
- bowel operations - consider enteric organisms
- predisposing factors
 - patient characteristics: age, diabetes, steroids, immunosuppression, malnutrition, patient with other infections, traumatic wound, radiation
 - other factors: prolonged preoperative hospitalization, duration of surgery, break in sterile technique, use of drains, multiple antibiotics
- clinical presentation
 - typically fever POD 3-4
 - pain, wound erythema, induration, frank pus or purulosanguinous discharge
- treatment
 - re-open affected part of incision, culture wound, pack, heal by secondary intention

- antibiotics generally not indicated unless cellulitis or immunodeficiency present
- prophylaxis
 - consider IV antibiotics
 - debridement of necrotic and non-viable tissue

Wound Hemorrhage/Hematoma

- inadequate surgical control of hemostasis
- patients on anticoagulant therapy, myeloproliferative disorders (e.g. polycythemia vera)
- symptoms: pain, swelling, discoloration of wound edges, leakage

Wound Dehiscence

- definition - disruption of fascial layer, abdominal contents contained by skin
- evisceration - disruption of all abdominal wall layers and extrusion of abdominal contents (mortality of 15%)
- incidence = 0.3-5% of abdominal incisions
- usually POD 5-8
- most common presenting sign is sero-sanguinous drainage from wound
- predisposing factors
 - local
 - poor closure, increased intra-abdominal pressure (e.g. COPD, ileus, bowel obstruction), poor wound healing (hemorrhage, infection)
 - systemic
 - hypoproteinemia, steroids, age, diabetes, immunosuppression, sepsis, jaundice
- treatment - operative closure
 - evisceration is a surgical emergency
 - mild dehiscence can be treated expectantly with delayed repair of the resulting hernia

URINARY AND RENAL COMPLICATIONS

Urinary Retention

- may occur after any operation with GA or spinal anesthesia
- more likely in older males with history of prostatism
- treatment - bladder catheterization

Acute Renal Failure (see Nephrology Notes)

- high associated mortality > 50%
- classified according to primary cause e.g. pre-renal, renal, post-renal
- treatment - according to underlying cause
- decreased renal perfusion treated with fluid boluses
- consider CVP line or Swan-Ganz catheter if patient does not respond to fluid bolus

RESPIRATORY COMPLICATIONS

Atelectasis

- comprises 90% of post-op pulmonary complications
- clinical manifestations usually in first 24 hours post-op
 - low fever, tachycardia, crackles, decreased breath sounds, bronchial breathing, cyanosis
- pre-operative prophylaxis
 - quit smoking
 - deep abdominal breathing and coughing
- post-operative prophylaxis
 - incentive spirometry
 - minimize use of depressant drugs
 - good pain control
 - frequent changes in position
 - deep breathing and coughing
 - early ambulation

Aspiration Pneumonitis

- aspiration of gastric contents
- can be lethal
- major determinant of degree of injury is gastric pH
- occurs most often at time of anesthetic induction and at extubation

- treatment
 - immediate removal of debris and fluid from airway
 - consider endotracheal intubation and flexible bronchoscopic aspiration
 - IV antibiotics to cover oral aerobes and anaerobes

Pulmonary Edema

- occurs during or immediately after operation
- results from circulatory overload
 - overzealous volume replacement
 - left ventricular failure
 - shift of fluid from peripheral to pulmonary vascular bed
 - negative airway pressure
 - alveolar injury due to toxins
- treatment
 - O₂
 - remove obstructing fluid
 - correct circulatory overload
 - diuretics, PEEP in intubated patient

Respiratory Failure

- clinical manifestations - dyspnea, cyanosis, evidence of obstructive lung disease, pulmonary edema, unexplained decrease in PaO₂
- earliest manifestations - tachypnea and hypoxemia
 - NB: hypoxemia may initially present with confusion/delerium
- treatment
 - O₂ by mask
 - pulmonary toilet
 - bronchodilators
 - treatment of acute respiratory insufficiency - mechanical ventilation
- if these measures fail to keep PaO₂ > 60, consider ARDS
- control of post-operative pain can decrease pulmonary complications
 - problematic with thoracic and upper abdominal operations

CARDIAC COMPLICATIONS

- abnormal ECGs common in post-operative period
- compare with pre-op ECG
- common arrhythmia - SVT

Myocardial Infarction

- surgery increases risk of MI
- majority of cases on operative day or within first 3 postoperative days
- incidence
 - 0.5% in previously asymptomatic men > 50 years old
 - 40-fold increase in men > 50 years old with previous MI
- risk factors
 - pre-operative hypertension
 - pre-operative CHF
 - operations > 3 hours
 - intra-operative hypotension
 - angina pectoris
 - MI in 6 months preceding surgery

PARALYTIC ILEUS

- normal bowel sounds disappear following abdominal surgery
- also follows peritonitis, abdominal trauma, and immobilization
- return of GI motility following abdominal surgery varies
 - small bowel motility returns by 24-48 hours
 - gastric motility returns by 48 hours
 - colonic motility - up to 3-5 days
- due to paralysis of myenteric plexus
- two forms
 - intestinal ileus
 - gastric dilatation
- symptoms
 - abdominal distension and vomiting
 - absent or tinkly bowel sounds

- treatment
 - NG tube and fluid resuscitation
 - for prolonged ileus, consider TPN

POST-OPERATIVE DELIRIUM

- disturbance of sleep-wake cycle
- disturbance of attention
- fluctuating course throughout day
- incidence: 40% (likely an underestimate)
- under-recognized (28% missed)
- no correlation with type of anesthetic agent
- risk factors
 - > 50 years old
 - pre-existing cognitive dysfunction
 - depression
 - peri-operative biochemical derangements
 - > 5 prescribed medications post-operatively
 - use of anticholinergic medications preoperatively
 - cardiopulmonary bypass
 - ICU setting

POST-OPERATIVE FEVER

- fever does not necessarily imply infection
- timing of fever may help identify cause
- "6W's" - CLINICAL PEARL
 - Wind (pulmonary)
 - Water (urine-UTI)
 - Wound
 - Walk (DVT-PE)
 - Wonder drugs (drug fever)
 - Wanes (rhymes with veins: IV sites)
- 0-48 hours
 - usually atelectasis
 - consider early wound infection (especially *Clostridia*, Group A Strep)
 - leakage of bowel anastomosis (tachycardia, hypotension, oliguria, abdominal pain)
 - aspiration pneumonia
- POD \geq 3
 - after day 3 infections more likely
 - UTI- patient instrumented? e.g. foley
 - wound infection (usually POD 3-5)
 - IV site - especially IVs in place > 3 days
 - septic thrombophlebitis
 - intra-abdominal abscess (usually POD 5-10)
 - DVT (POD 7-10)
- also consider - cholecystitis, PE, sinusitis, prostatitis, peri-rectal abscess, drug fever, URTI, factitious fever

INTRA-ABDOMINAL ABSCESS

- localized intra-abdominal infection
- a collection of pus walled-off from rest of peritoneal cavity by inflammatory adhesions and viscera
- number of bacteria exceed host's ability to terminate infection
- danger: may perforate secondarily \rightarrow diffuse bacterial peritonitis
- usually polymicrobial
- clinical manifestations
 - persistent, spiking fever, dull pain, weight loss, leukocytosis
 - impaired function of adjacent organs e.g. ileus or diarrhea (with rectal abscess)
 - co-existing effusion e.g. pleural effusion with subphrenic abscess
- diagnosis
 - usually by U/S or CT
 - don't forget to perform DRE (boggy mass in pelvis)
- treatment
 - drainage is essential
 - antibiotics to cover aerobes and anaerobes

Martin, RF, Rossi, RL. The Acute Abdomen: An Overview and Algorithms. *Surg Clin North Am.* 1997;77(6):1227-43.

SPECIFIC "SIGNS" ON PHYSICAL EXAMINATION

- Blumberg's sign (rebound tenderness): constant, held pressure with sudden release causes severe tenderness (peritoneal irritation)
- Courvoisier's sign: palpable, non-tender gall bladder with jaundice (pancreatic or biliary malignancy)
- Cullen's sign: purple-blue discoloration around umbilicus (peritoneal hemorrhage)
- Grey Turner's sign: flank discoloration (retroperitoneal hemorrhage)
- iliopsoas sign: flexion of hip against resistance or passive hyperextension of hip causes pain (retrocecal appendix)
- Murphy's sign: inspiratory arrest on deep palpation of RUQ (cholecystitis)
- McBurney's point tenderness: 1/3 from anterior superior iliac spine to umbilicus; indicates local peritoneal irritation (appendicitis)
- obturator sign: flexion then external or internal rotation about the right hip causes pain (pelvic appendicitis)
- percussion tenderness: often good substitute for rebound tenderness
- Rovsing's sign: palpation pressure to left abdomen causes RLQ McBurney's point tenderness (appendicitis)
- shake tenderness: peritoneal irritation (bump side of bed in suspected malingers)

EVALUATION

History

- pain
 - location of pain
 - see Table 1
 - also consider: abdominal wall disorders (e.g. hematoma, herpes zoster)
 - referred pain
 - biliary colic: right shoulder or scapula
 - renal colic: to groin
 - appendicitis: epigastric to RLQ
 - pancreatitis: to back
 - ruptured aortic aneurysm: to back or flank
 - perforated ulcer: to RLQ (right paracolic gutter)
- associated symptoms
 - general: fevers, chills, weight loss, jaundice
 - gastrointestinal: anorexia, nausea, vomiting, diarrhea, constipation, obstipation, melena, hematochezia
 - urinary: dysuria, hematuria, urinary frequency
 - gynecological: 1st day LMP, vaginal discharge, previous STD, IUD use

Table 1. Location of Pain

Right Upper Quadrant	Left Upper Quadrant
gallbladder/biliary tract hepatitis, hepatic abscess peptic ulcer pancreatitis MI pneumonia/pleurisy empyema, pericarditis	pancreatitis splenic rupture, infarct splenic aneurysm gastritis MI pneumonia empyema
Right Lower Quadrant	Left Lower Quadrant
appendicitis intestinal obstruction diverticulitis ulcer perforation ectopic pregnancy ovarian cyst or torsion salpingitis ureteral calculi endometriosis typhlitis	leaking aneurysm intestinal obstruction diverticulitis psoas abscess ectopic pregnancy ovarian cyst or torsion salpingitis ureteral calculi endometriosis

Physical Exam and Work-Up

- steps in physical exam
 - 1) general observation: patient position (i.e. lying still vs. writhing)
 - 2) vitals: postural changes, fever
 - 3) status of hydration
 - 4) cardiovascular/respiratory examination
 - 5) abdominal examination
 - observation: distention, scars, visible peristalsis
 - auscultation: absent, decreased, normal, increased bowel sounds
 - percussion: hypertympanic sounds in bowel obstruction, percussion tenderness indicative of peritonitis
 - palpation: tenderness, abdominal masses
 - 6) CVA tenderness
 - 7) specific signs
 - 8) hernias, male genitalia
 - 9) rectal/pelvic exam
- labs
 - CBC and differential
 - electrolytes, BUN, creatinine
 - amylase levels
 - liver function tests
 - urinalysis
 - stool for occult blood
 - others as indicated
 - ECG, β -hCG, ABG, septic workup, lactate (ischemic bowel)
- radiology
 - 3 views abdomen
 - CXR
 - others as indicated
 - U/S, CT, endoscopy, IVP, peritoneal lavage, laparoscopy
- indications for urgent operation
 - physical findings
 - peritonitis
 - severe or increasing localized tenderness
 - progressive distension
 - tender mass with fever or hypotension (abscess)
 - septicemia and abdominal findings
 - bleeding and abdominal findings
 - suspected bowel ischemia (acidosis, fever, tachycardia)
 - deterioration on conservative treatment
 - radiologic
 - free air
 - massive bowel distention (colon > 12 cm)
 - space occupying lesion with fever
 - endoscopic
 - perforation
 - uncontrollable bleeding
 - paracentesis
 - blood, pus, bile, feces, urine

Approach to the Critically Ill Surgical Patient

ABC, I'M FINE

ABC - see Emergency Medicine Notes

I - IV: two large bore IV's with normal saline, wide open

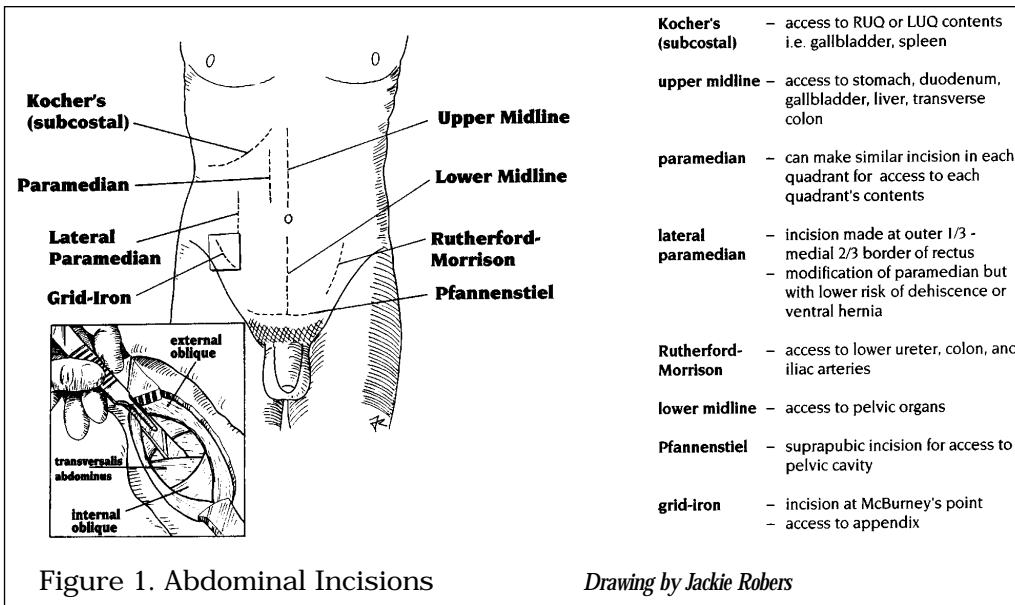
M - Monitors: O₂ sat, EKG, BP

F - Foley catheter to measure urine output

I - Investigations: see above

N - +/- NG tube

E - Ex rays



Layers of the Abdominal Wall

- skin
- superficial fascia
 - Camper's fascia --> dartos muscle
 - Scarpa's fascia --> Colles' fascia
- muscle
 - external oblique --> inguinal ligament, external spermatic fascia, fascia lata
 - internal oblique --> cremasteric muscle
 - transversalis abdominis --> posterior inguinal wall
- transversalis fascia --> internal spermatic fascia
- peritoneum --> tunica vaginalis
- at midline
 - rectus abdominis muscle: in rectus sheath, divided by linea alba
 - above semicircular line of Douglas (midway between symphysis pubis and umbilicus):
 - anterior rectus sheath = external oblique aponeurosis and anterior leaf of internal oblique aponeurosis
 - posterior rectus sheath = posterior leaf of internal oblique aponeurosis and transversus
 - below semicircular line of Douglas:
 - anterior rectus sheath = aponeurosis of external, internal oblique, transversus
- arteries: superior epigastric (branch of internal thoracic), inferior epigastric (branch of external iliac), both arteries anastomose and lie behind the rectus muscle

HIATUS HERNIA

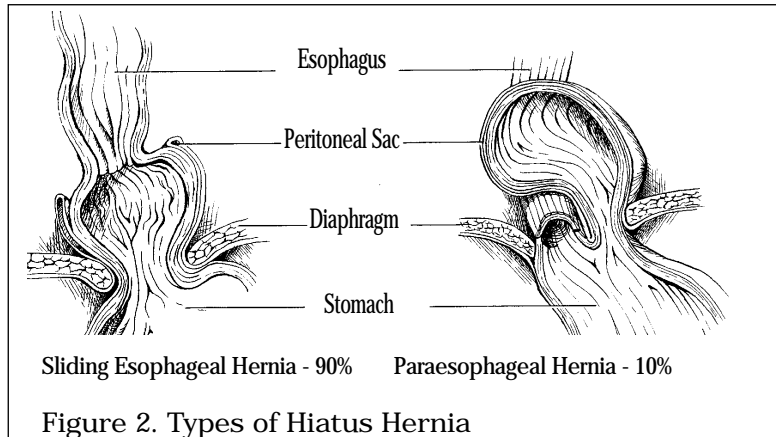


Figure 2. Types of Hiatus Hernia

Drawings by Bryce Hough

Sliding Hiatus Hernia (Type I)

- ❑ upward displacement of gastroesophageal junction into chest
- ❑ 90% of esophageal hernias
- ❑ associated with aging, weakening of musculofascial structure, and increased intra-abdominal pressure (e.g. obesity, pregnancy)
- ❑ clinical presentation
 - heartburn - after meals and at night
 - relief with sitting, standing, water, antacids
 - regurgitation of gastric contents (often acidic) into esophagus
 - complications: esophagitis, chronic occult GI blood loss with anemia, ulceration, dysphagia due to lower esophageal stricture, Barrett's esophagus, adenocarcinoma, pneumonia (aspiration)
- ❑ differential diagnosis: cholelithiasis, diverticulitis, peptic ulcer, achalasia, MI, angina
- ❑ investigation
 - gastroscopy with biopsy → document type and extent of tissue damage, rule out Barrett's esophagus and cancer
 - 24 hour esophageal pH monitoring → often used if atypical presentation, gives information about frequency and duration of acid reflux, correlation of symptoms with signs
 - esophageal manometry → detects decreased lower esophageal sphincter pressure; may diagnose motility disorder
 - upper GI series or barium swallow
 - CXR globular shadow with air-fluid level over cardiac silhouette, visible shadow posterior mediastinum on lateral view
- ❑ treatment
 - conservative
 - stop smoking
 - weight loss
 - elevate head of bed
 - no nocturnal meals
 - smaller and more frequent meals
 - avoid alcohol, coffee, fat
 - medical
 - antacids
 - H₂ antagonists (e.g. cimetidine, ranitidine)
 - proton pump inhibitor e.g. omeprazole (Losec) x 8-12 weeks for esophagitis
 - adjuvant prokinetic agents may play a role e.g. cisapride - increases lower esophageal pressure, enhances gastric emptying
 - surgical (< 10%)
 - Nissen fundoplication or laparoscopic Nissen where fundus of stomach is wrapped around the LES

- 90% success rate
- indications for surgery
 - complications of sliding hernia or gastroesophageal reflux (especially stricture, severe ulceration, fibrosis)
 - symptoms refractory to conservative and medical treatment
 - complete mechanical failure of lower esophageal sphincter (LES)

Paraesophageal Hiatus Hernia (Type II)

- gastroesophageal junction undisplaced and stomach fundus herniates into chest (other bowel loops, spleen may also herniate with fundus)
- 10% of esophageal hernias
- clinical presentation
 - asymptomatic
 - heartburn/reflux uncommon
 - pressure sensation in lower chest, dysphagia
- complications
 - hemorrhage
 - incarceration, obstruction, and strangulation
 - palpitations rarely
- treatment
 - surgery in almost every case to prevent severe complications
 - procedure: reduce hernia, suture to posterior rectus sheath (gastropexy), close defect in hiatus
 - excellent results

Mixed Hiatus Hernia (Type III)

- a combination of Types I and II

STRUCTURAL LESIONS (see Gastroenterology Notes)

MOTILITY DISORDERS (see Gastroenterology Notes)

OTHER DISORDERS

- esophageal varices (see Liver Section)

Mallory Weiss Tear (see Gastroenterology Notes)

ESOPHAGEAL PERFORATION

- etiology: esophagus at risk of rupture due to lack of serosa
 - instrumental: endoscopy, dilation, biopsy, intubation, placement of NG tubes
 - spontaneous (Boerhaave's syndrome) due to frequent and forceful vomiting, common in alcoholics and bulimics
 - trauma
 - corrosive injury
 - carcinoma
- clinical presentation: neck, chest or upper abdominal pain, dyspnea, subcutaneous emphysema, pneumothorax, fever
- differential diagnosis: MI, dissecting aortic aneurysm, pulmonary embolus
- diagnosis
 - CXR shows pneumothorax, pneumomediastinum, pleural effusion, subdiaphragmatic air
 - swallowing study with water soluble contrast (hypoaque)
- treatment: NPO, fluid resuscitation, IV antibiotics, early surgical repair (less than 24 hours to prevent infection and subsequent repair failure)

ESOPHAGEAL CARCINOMA

- epidemiology
 - 1% of all malignant lesions

- male:female = 3:1
- 50-60 years of age
- increased incidence in Blacks, especially squamous cell carcinoma
- ❑ risk factors
 - physical agents: alcohol, tobacco, nitrosamines, lye, radiation
 - structural: diverticula, hiatus hernia, achalasia
 - Barrett's epithelium (8-10% risk of adenocarcinoma, monitor every 1-2 years by endoscopy and biopsy)
 - chronic iron deficiency (Plummer-Vinson syndrome)
- ❑ pathology
 - upper 20-33%, middle 33%, lower 33-50%
 - squamous cell carcinoma: 80-85% (mid-esophagus)
 - adenocarcinoma: 5-10% but incidence rising in U.S.
 - up to 40-50% (lower esophagus) - associated with Barrett's esophagus
- ❑ clinical presentation
 - frequently asymptomatic - late presentation
 - often dysphagia, first for solids then liquids
 - weight loss, weakness
 - regurgitation and aspiration (aspiration pneumonia)
 - hematemesis, anemia
 - odynophagia then constant pain
 - tracheoesophageal, bronchoesophageal fistula
 - vocal cord paralysis
 - spread directly or via blood and lymphatics - trachea (coughing), recurrent laryngeal nerves (hoarseness), aorta, liver, lung, bone, celiac and mediastinal nodes
- ❑ diagnosis and investigations
 - barium swallow first - narrowing site of lesion (shelf or annular lesion)
 - esophagoscopy - biopsy for tissue diagnosis and extent of tumour
 - bronchoscopy - for upper and mid esophageal lesions due to high incidence of spread to tracheobronchial tree
 - CT scan: for staging - adrenal, liver, lung, bone metastases
- ❑ treatment
 - surgery
 - lower third
 - thoracic esophagectomy, pyloroplasty (or pyloromyotomy) and celiac lymph node resection
 - reconstruction of GI continuity with either stomach or colon
 - middle or upper third
 - esophagectomy extends to cervical esophagus
 - anastomosis performed through separate neck incision
 - check margins by frozen section during surgery
 - contraindications: invasion of tracheobronchial tree or great vessels, lesion > 10 cm
 - radiation
 - if unresectable, palliation (relief of dysphagia in 2/3 of patients, usually transient)
 - chemotherapy
 - alone, or pre and post-operatively
 - multimodal - combined chemotherapy, radiation and surgery
 - palliative or cure, survival rates higher than surgery alone
 - palliative treatment
 - resection, bypass, dilation and stent placement, laser ablation
- prognosis
 - 5-8% operative death rate
 - 12% five-year survival (Stage I) post surgery
 - prognosis slightly better if squamous cell carcinoma

GASTRIC ULCERS (see Gastroenterology Notes)

- ❑ surgical management
 - rare due to *H. pylori* and medical treatment
- ❑ indications for surgery
 - unresponsive to medical treatment (may be malignant)
 - dysplasia or carcinoma
 - hemorrhage - 3x risk of bleeding as compared to duodenal ulcers
 - obstruction, perforation, penetration
- ❑ procedures
 - hemigastrectomy via Billroth I or Billroth II (see Figure 3)
 - always biopsy ulcer for malignancy
 - always operate if fails to heal completely, even if biopsy negative - could be primary gastric lymphoma
 - vagotomy and pyloroplasty only indicated in acid hypersecretion (rare)

DUODENAL ULCERS (see Gastroenterology Notes)

- ❑ most within 2 cm of pylorus
- ❑ complications
 - perforation usually if ulcer on anterior surface
 - sudden onset of pain and collapse
 - acute abdomen, rigid, board-like
 - no bowel sounds, ileus
 - initial chemical peritonitis followed by bacterial peritonitis
 - diagnosis: CXR - free air under diaphragm (70% of patients)
 - treatment: oversew ulcer (plication) and omental patch
 - posterior penetration
 - into pancreas (elevated amylase)
 - constant mid-epigastric pain burrowing into back, unrelated to meals
 - posterior hemorrhage
 - gastroduodenal artery involvement
 - initial resuscitation with crystalloids, blood transfusion for hypotension and hypovolemia
 - diagnostic and/or therapeutic endoscopy (i.e. laser, cautery, injection)
 - surgery if bleeding severe or recurrent
 - procedure: pyloroplasty, truncal vagotomy or vagotomy with antrectomy
 - gastric outlet obstruction
 - due to edema, spasm, fibrosis of pyloric channel
 - nausea and vomiting (undigested food, non-bilious), dilated stomach, crampy abdominal pain
 - succussion splash
 - surgery after NG decompression and correction of hypochloremic, hypokalemic metabolic alkalosis
 - procedure: vagotomy with antrectomy or vagotomy with drainage
- ❑ surgical management
 - indications: persistent bleeding > 8 units, rebleed in hospital, rare blood types, Jehovah's Witness, perforation, gastric outlet obstruction, intractable pain despite medical management
- ❑ procedures
 - truncal vagotomy and drainage via pyloroplasty
 - best combination of safety and effectiveness
 - 5-10% recurrence, but low complication rate
 - truncal vagotomy and antrectomy with Billroth I or II anastomosis
 - low recurrence (less than 2%)
 - highest morbidity (dumping, diarrhea) and mortality
 - highly selective vagotomy
 - high recurrence rate (up to 25%)
- ❑ complications following surgery: recurrent ulcer, retained antrum, fistula (gastrocolic/gastrojejunal), dumping syndrome, anemia, postvagotomy diarrhea, afferent loop syndrome

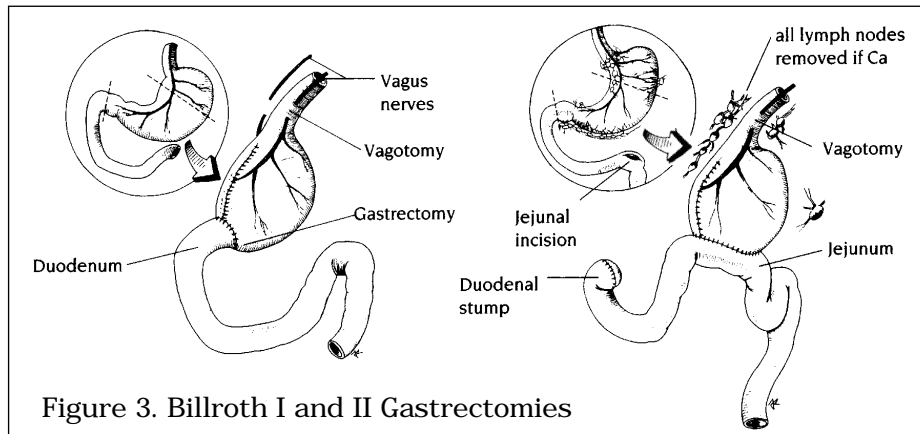


Figure 3. Billroth I and II Gastrectomies

Drawings by Jackie Robers

GASTRIC CARCINOMA

Latif, A. Gastric Cancer Update on Diagnosis, Staging and Therapy. *Postgraduate Medicine*. 1997;102(4):231-6.

□ epidemiology

- male:female = 2:1
- most common age group 50-59 years
- decreased by 2/3 in past 50 years

□ risk factors

- smoking
- alcohol
- smoked food, nitrosamines
- *H. pylori* causing chronic atrophic gastritis
- pernicious anemia associated with achlorhydria and chronic atrophic gastritis
- gastric adenomatous polyps
- previous partial gastrectomy (> 10 years post-gastrectomy)
- hypertrophic gastropathy
- hereditary nonpolyposis colon cancer

□ pathology

- histology
 - 92% adenocarcinoma (8% lymphoma, leiomyosarcoma)
- morphology - Borrmann classification
 - polypoid (25%)
 - ulcerative (25%)
 - superficial spreading (15%)
 - linitis plastica (10%) - diffusely infiltrating
 - advanced/diffuse (35%) - tumour has outgrown above 4 categories

□ clinical presentation

- suspect when ulcer fails to heal or is on greater curvature of stomach and cardia
- usually late onset of symptoms
- insidious onset of: postprandial abdominal fullness, weight loss, anorexia, vague abdominal pain, dysphagia, hematemesis, epigastric mass (25%), hepatomegaly, fecal occult blood, iron-deficiency anemia, melena
- rarely: Virchow's node (left supraclavicular node), Blumer's shelf (palpable mass in pouch of Douglas in pelvis), Krukenberg tumour (mets to ovary), Sister Mary Joseph nodule (umbilical nodule), malignant ascites
- spread: liver, lung, brain

□ diagnosis

- EGD and biopsy, upper GI series with air contrast (poor sensitivity if previous gastric surgery)
- CT for distant metastases

□ staging (see Table 2)

Stage	Criteria	Prognosis (5 year survival)
I	mucosa and submucosa	70%
II	extension to muscularis propria	30%
III	extension to regional nodes	10%
IV	distant metastases or involvement of continuous structures	0%
overall		10%

TNM CLASSIFICATION

Primary Tumour (T)

- T₁ limited to mucosa and submucosa
- T₂ extends into, but not through, serosa
- T₃ through serosa, does not invade other structures
- T₄ through serosa and invades contiguous structures

Nodal Involvement (N)

- N₀ no lymph nodes involved
- N₁ involvement of nodes within 3 cm of the primary tumour
- N₂ involvement of nodes more than 3 cm from primary tumour which are removable at operation, including those along left gastric, splenic, celiac and common hepatic arteries
- N₃ involvement of intra-abdominal lymph nodes not removable at operation including para-aortic, hepatoduodenal, retropancreatic, and mesenteric

Distant Metastasis (M)

- M₀ no known distant metastasis
- M₁ distant metastasis present

Stage	TNM Classification		
0	T1S	N0	M0
IA	T1	N0	M0
IB	T1	N1	M0
	T2	N0	M0
II	T1	N2	M0
	T2	N1	M0
	T3	N0	M0
IIIA	T2	N2	M0
	T3	N1	M0
IIIB	T4	N0	M0
	T3	N2	M0
IV	T4	N1	M0
	T4	N2	M0
	Any T	Any N	M1

- treatment: surgery for adenocarcinoma
 - proximal lesions
 - total gastrectomy and esophagojejunostomy (Roux-en-Y)
 - include lymph node drainage to clear celiac axis (may require splenectomy)
 - distal lesions
 - distal radical gastrectomy (wide margins, en bloc removal of omentum and lymph node drainage)
 - palliation
 - gastric resection to decrease bleeding and to relieve obstruction thus enabling the patient to eat
 - overall 5 year survival - 10%
 - lymphoma
 - chemotherapy ± surgery ± radiation

COMPLICATIONS OF GASTRIC SURGERY

- general
 - anesthetic reaction
 - post-op complications
- specific
 - alkaline reflux gastritis
 - duodenal contents reflux into stomach
 - common postgastrectomy (25%)
 - postprandial epigastric pain, nausea, vomiting, weight loss, anemia
 - diagnosis: endoscopy and biopsy (gastritis, bile reflux)
 - treatment: conversion of Billroth I or II to Roux-en-Y anastomosis
 - afferent loop syndrome - occurs with Billroth II
 - early postprandial distention, pain, nausea, bilious vomiting
 - caused by intermittent mechanical obstruction and distension of afferent limb
 - treated by increasing drainage of afferent loop by conversion to Roux-en-Y
 - dumping syndrome
 - seen in postgastrectomy patients
 - early - caused by hypertonic chyme release into small bowel resulting in fluid accumulation and jejunal distention
 - late - due to large glucose load leading to large insulin release and hypoglycemia
 - post-prandial symptoms: epigastric fullness or pain, nausea, palpitations, dizziness, diarrhea, tachycardia
 - treatment: low carbohydrate, high fat and protein diet, delay gastric emptying by interposition of antiperistaltic jejunal loop between stomach and small bowel
 - treatment: small snack 2 hours after meals
 - postvagotomy diarrhea (up to 25%)
 - usually improves

BOWEL OBSTRUCTION

SMALL BOWEL OBSTRUCTION

- etiology
 - adhesions (60%) in patient with prior abdominal operations
 - hernias (15%)
 - neoplasms (15%)
- also associated with
 - cystic fibrosis
 - SMA syndrome
 - annular pancreas
 - volvulus
 - inflammatory lesions: Crohn's, radiation enteritis/stricture
 - intraluminal obstruction: gallstone ileus, intussusception
 - foreign body (bezoars, barium, worms)
- clinical presentation
 - non-strangulating obstruction - proximal, middle, or distal
 - proximal obstruction
 - profuse early vomiting (often bilious) - dehydration
 - colicky abdominal pain
 - minimal abdominal distension
 - middle level obstruction
 - moderate vomiting after onset of pain
 - abdominal distension
 - intermittent colicky pain
 - obstipation
 - distal obstruction
 - late feculent vomiting
 - marked abdominal distension and peristaltic rushes
 - obstipation, variable pain

- strangulating - surgical emergency
 - impaired blood supply, leads to necrosis
 - early shock
 - fever + increased WBC count
 - cramping pain turns to continuous ache
 - vomiting gross or occult blood
 - abdominal tenderness or rigidity
- ❑ radiological (see Colour Atlas C1)
 - CXR, abdominal x-ray (3 views)
 - dilated edematous loops of small bowel (ladder pattern - plica circularae)
 - air-fluid levels
 - colon often devoid of gas unless only partial obstruction
- ❑ laboratory
 - normal early
 - hemoconcentration
 - leukocytosis (marked in strangulation)
 - increased amylase
 - metabolic alkalosis → proximal SBO
 - metabolic acidosis → bowel infarction
- ❑ treatment
 - 1) NG tube to relieve vomiting and abdominal distention
 - 2) stabilize vitals, fluid and electrolyte resuscitation
 - 3) if partial SBO (i.e. if passage of stool, flatus) → conservative management
 - 4) if complete SBO (obstipation) → surgery (cannot rule out strangulation)
 - 5) trial of medical management may be indicated in Crohn's, recurrent small bowel obstruction, carcinomatosis
- ❑ prognosis
 - mortality: non-strangulating 2%, strangulating 8% (25% if > 36 hours)
- ❑ complications
 - open perforation
 - septicemia
 - hypovolemia

	Small bowel obstruction	Paralytic ileus
nausea and vomiting	+	+
abdominal distention	+	+
obstipation	+	+
abdominal pain	crampy	minimal or absent
bowel sounds	normal, increased	absent, decreased
AXR	ladder pattern, air fluid levels, no gas in colon	gas present throughout small and large colon

LARGE BOWEL OBSTRUCTION

- ❑ etiology
 - colon carcinoma 60%
 - diverticulitis 20%
 - volvulus 5%
- ❑ other causes of large bowel obstruction
 - IBD
 - benign tumours
 - fecal impaction/foreign body
 - adhesions
 - hernia (especially sliding type)
 - intussusception (children)
 - endometriosis

- ❑ clinical presentation
 - slower in onset, less pain, later onset of vomiting, less fluid/electrolyte disturbance than small bowel obstruction
 - crampy abdominal pain in hypogastrium
 - continuous, severe abdominal pain in ischemia, peritonitis
 - distension, constipation, obstipation, anorexia
 - nausea and late feculent vomiting
 - high-pitched (borborygmi) or absent bowel sounds
 - may have visible peristaltic waves
 - open loop (safe): 10-20%
 - incompetent ileocecal valve allows relief of colonic pressure as contents reflux into ileum
 - closed loop (dangerous): 80-90%
 - ileocecal valve competent, allowing build up of colonic pressures to dangerous level
 - compromise of lymphatic, venous and arterial circulation → infarction
 - cecum at greatest risk of perforation due to Laplace's Law (Pressure = wall tension/radius)
 - high risk of perforation if cecum diameter > 12 cm on AXR
 - suspect impending perforation in the presence of tenderness over the cecum
 - if obstruction at ileocecal valve → symptoms of SBO
- ❑ diagnosis
 - x-ray: "picture frame" appearance
 - hypaque enema
 - do not use contrast - may become inspissated and convert partial to complete LBO
- ❑ treatment
 - goal: decompression to prevent perforation
 - correct fluid and electrolyte imbalance
 - surgical correction of obstruction (usually requires temporary colostomy)
 - volvulus: sigmoidoscopic decompression or barium enema followed by operative reduction if unsuccessful
- ❑ prognosis
 - dependent upon age, general medical condition, vascular impairment of bowel, perforation, promptness of surgical management
- ❑ mortality
 - overall: 20%
 - cecal perforation: 40%
- ❑ Ogilvie's syndrome: pseudo-obstruction, distention of colon without mechanical obstruction
 - associations: long term debilitation, chronic disease, immobility, narcotic use, polypharmacy, recent orthopedic surgery, post-partum
 - diagnosis: cecal dilatation on AXR, if diameter > 12 cm, largely increased risk of perforation
 - treatment: decompression with enema, if unsuccessful, decompression with colonoscope, nasogastric tube, rectal tube; if perforation or ischemia, surgery

TUMOURS OF SMALL INTESTINE

- ❑ very rare (1-5% of GI tumours)
- ❑ usually present with bleeding and obstruction often because of intussusception

Benign

- ❑ usually asymptomatic
- ❑ 10 times more common than malignant
- ❑ most common sites: terminal ileum, proximal jejunum
- ❑ types
 - polyps
 - adenomatous, villous - rare
 - familial adenomatous polyposis
 - multiple intestinal polyps in association with desmoid tumours, mandible or skull osteomas, sebaceous cysts
 - malignant degeneration of polyps common
 - hamartomatous - overgrowth and abnormal arrangement of normal cells
 - associated with Peutz-Jegher's syndrome
 - multiple polypoid hamartomas and mucocutaneous pigmentation (perioral, also on palms of hands and soles of feet)
 - rarely malignant
 - autosomal dominant inheritance
 - treatment: surgical
 - juvenile polyps
 - other (e.g. leiomyomas, lipomas, adenomas, hemangiomas, etc...)

Malignant

- ❑ types
 - adenocarcinoma 40%
 - carcinoid 50%
 - lymphoma 20%
 - other (e.g. sarcoma, metastases)
- ❑ adenocarcinoma (most common primary tumour of small intestine)
 - 40-50% in duodenum, incidence decreases distally
 - higher risk in Crohn's disease
 - 80% metastatic at time of operation
 - 5 year survival 25%
 - often asymptomatic, can cause SBO
 - diagnosis - small bowel follow through or enteroclysis
- ❑ carcinoid
 - enterochromaffin cell origin (APUDoma: amine precursor uptake and decarboxylation), may be associated with MEN I and II
 - often slow-growing
 - sites (prognosis related to size)
 - appendix - 46%
 - distal ileum - 28%
 - rectum- 17%
 - lung, breast
 - clinical presentation
 - crampy abdominal pain, bleeding, obstruction
 - carcinoid syndrome (< 10%): requires liver involvement, +/- mets to bronchi, ovaries, testes; secretes serotonin, kinins and vasoactive peptides directly to systemic circulation (normally inactivated by the liver)
 - results in hot flushes, diarrhea, bronchoconstriction (wheezing), hypotension (vascular collapse), and tricuspid and/or pulmonic valve insufficiency (collagen deposition)
 - diagnosis: most found at surgery for obstruction or appendectomy, elevated 5-HIAA (breakdown product of serotonin) in urine, or increased 5-HT in blood
 - treatment: resect tumour and mets, +/- chemotherapy, treat carcinoid syndrome (steroids, histamine, octreotide)
 - metastatic risk - 2% if size < 1 cm, 90% if > 2 cm
 - 5 year survival 70% unless liver mets (20%)

- lymphoma
 - proximal jejunum in patients with celiac disease
 - usually distal ileum
 - clinically: perforation followed by obstruction or bleeding
 - presents as fever, malabsorption, abdominal pain
 - treatment
 - low grade: chemotherapy with cyclophosphamide
 - high grade: surgical resection, radiation
 - palliative: somatostatin, doxorubicin
 - prognosis: 65-80% overall; 95% if localized
 - survival: 40% at 5 years

MECKEL'S DIVERTICULUM

- persistent vitelline duct remnant on antimesenteric border of ileum; can contain small intestinal, gastric, colonic, pancreatic mucosa
- most common diverticulum of GI tract
- rule of 2's: 2% of the population; symptomatic in 2% of cases; found within 2 feet (10-90 cm) of the ileocecal valve
- clinical presentation: bleeding, obstruction, inflammation (mimic appendicitis), intussusception, perforation
 - painless bleeding due to peptic ulceration of heterotropic gastric mucosa (50% of patients < 2 years old)
- investigations
 - technetium Tc99 can localize bleeding ectopic gastric mucosa
- treatment: fluid and electrolyte restoration, surgical resection if symptomatic

APPENDIX

APPENDICITIS

- epidemiology
 - 6% of population
 - 80% between 5-35 years of age
 - atypical presentation in very young and very old
- pathogenesis
 - luminal obstruction of appendix
 - children to young adult: hyperplasia of submucosal lymphoid follicles
 - adult: fecolith
 - more rarely: tumour, stricture, foreign body
 - obstruction → bacterial overgrowth → inflammation/swelling → ischemia → gangrene/perforation
- clinical presentation
 - only reliable feature is progression of signs and symptoms
 - low grade fever
 - vague mid abdominal discomfort or crampy pain
 - anorexia, nausea and vomiting after pain starts
 - migration of pain to RLQ (localized)
 - tenderness at McBurney's point, RLQ on rectal exam
 - positive Rovsing's sign, rebound tenderness, psoas sign, obturator sign
- diagnosis
 - mild leukocytosis with left shift unless perforation
 - x-rays: usually nonspecific; free air if perforated, look for calculus
 - consider CT scan
 - consider pelvic U/S or laparoscopy in female
- treatment
 - surgical (possible laparoscopy)
 - the decision to operate is acceptable even if only 70-80% are found to have true appendicitis
 - need to be aggressive, especially in young females since perforation may cause infertility due to tubal damage
 - morbidity/mortality 0.6% (uncomplicated), 5% if perforated
- complications
 - perforation
 - 25-30%
 - more common at extremes of age
 - increase in fever and pain

- peritonitis: local (if walled-off by omentum) or generalized
- appendiceal abscess (phlegmon)
 - presents as appendicitis plus RLQ mass
 - diagnosis by U/S or CT
 - interval appendectomy (6 weeks) as needed after optimal preparation (aspiration, antibiotics)

TUMOURS OF THE APPENDIX (rare)

- benign
 - most common type
 - usually an incidental finding
- malignant
 - carcinoid tumours
 - appendix is the most common location
 - may produce carcinoid syndrome with liver metastases
 - treatment: appendectomy if < 2 cm and not extending into serosa; right hemicolectomy if > 2 cm or obvious nodal involvement or base of appendix involved
 - adenocarcinoma
 - 50% present as acute appendicitis
 - spreads rapidly to lymph nodes, ovaries, and peritoneal surfaces
 - treatment: right hemicolectomy
 - malignant mucinous cystadenocarcinoma
 - usually present as abdominal distension and pain
 - treatment: appendectomy
 - prognosis: local recurrence is inevitable, mortality 50% at 5 years

INFLAMMATORY BOWEL DISEASE

CROHN'S DISEASE (see Gastroenterology Notes)
(see Colour Atlas C4)

Surgical Management

- intervention required in 70-75% of patients when complications arise
- goal of surgery is to conserve bowel - resect as little as possible
- indications
 - SBO due to stricture and inflammation ~ indication in 50% of surgical cases
 - fistula: enterocolic, vesicular, vaginal, cutaneous abscess
 - less common indications → perforation, hemorrhage, intractable disease (toxic megacolon), failure to thrive (especially children), perianal disease
- procedures
 - palliative, not curative
 - ileocecal resection with incidental appendectomy (unless base of appendix involved)
 - strictureplasty - widens lumen in chronically scarred bowel
 - exclusion bypass - bypass unresectable inflammatory mass, but later risk of cancer in excluded segment
- complications
 - short gut syndrome (diarrhea, steatorrhea, malnutrition)
 - fistulas
 - biliary stones (due to decreased bile salt absorption leading to increased cholesterol precipitation)
 - kidney stones (due to loss of Ca⁺⁺ in diarrhea leading to increased oxalate absorption and hyperoxaluria → stones)
- prognosis
 - recurrence rate at 10 years: ileocolic (50%), small bowel (50%), colonic (40-50%)
 - 80-85% of patients who need surgery lead normal lives
 - mortality 15% at 30 years
 - re-operation at 5 years: primary resection 20%, bypass 50%

ULCERATIVE COLITIS (see Gastroenterology Notes)
(see Colour Atlas C5)

Surgical Management

☐ indications

- emergency
 - hemorrhage
 - obstruction
 - perforation
 - toxic megacolon - leading cause of death in UC, 40% of cases fatal
- elective
 - poor control, unable to taper steroids
 - cancer risk
 - failure to thrive in children

☐ procedures

- if emergency: total colectomy and ileostomy, rectal preservation
- proctocolectomy and ileoanal anastomosis (operation of choice)
- proctocolectomy with permanent ileostomy for patients not candidates for ileoanal procedure

☐ prognosis

- mortality: 5% over 10 years
- 2% mortality with elective surgery
- 8-15% mortality with emergency surgery

☐ total proctocolectomy will completely eliminate risk of cancer

LARGE INTESTINE

DIVERTICULAR DISEASE (see Colour Atlas C3)

☐ terminology

- diverticulum - abnormal sac or pouch protruding from the wall of a hollow organ
- diverticulosis - presence of diverticula

☐ epidemiology

- 35-50% of general population (M=F)
- 95% involve sigmoid colon
- majority are asymptomatic (approximately 80%)
- higher incidence in Western countries, related to low fibre content in diet

☐ pathogenesis

- related to high intraluminal pressure and defects in the colonic wall
- fibre-deficient diet - increases gut transit time, causes hypertrophy of muscle wall which occludes GI lumen and causes increased pressure
- muscle wall weakness from aging and illness
- diverticula occur at greatest area of weakness, most commonly at the site of penetrating vessels, therefore increased risk of hemorrhage
- left sided (false) diverticula - contain only mucosal and submucosal layers (acquired)
- right sided (true) diverticula = contains all layers (congenital)

☐ clinical presentation

- asymptomatic (80%), recurrent abdominal pain (usually LLQ), constipation, diarrhea, or alternating bowel habits
- bleeding - 2/3 of all massive lower gastrointestinal bleeds
- diverticulitis

☐ treatment

- medical: high fibre diet, education, reassurance
- surgical: treat massive hemorrhage or rule out carcinoma

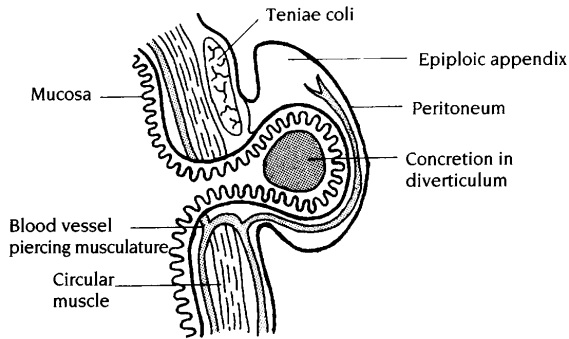
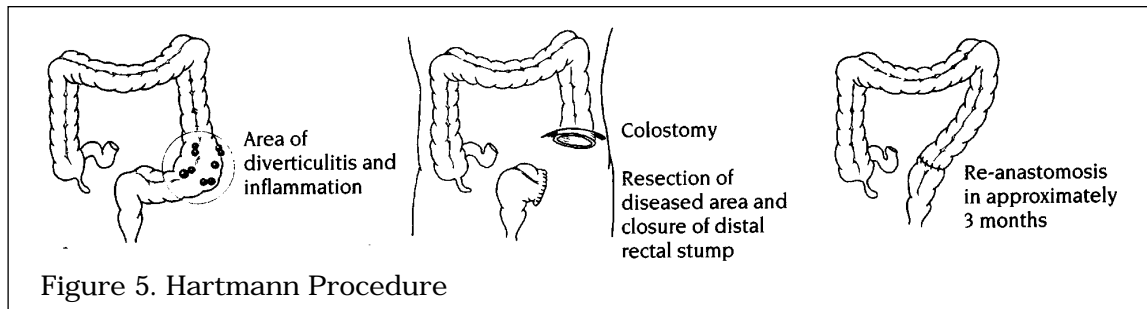


Figure 4. Cross-Section of Diverticulum

Drawing by Myra Rudakewich

Diverticulitis

- inflammation secondary to perforation or infection of diverticula
- often involves sigmoid colon
- clinical presentation
 - left lower quadrant (LLQ) pain and tenderness, palpable mass if phlegmon or abscess
 - constipation or frequent defecation common
 - occult or gross blood in stool less common
 - low-grade fever, leukocytosis
 - like a left-sided appendicitis
 - dysuria if inflammation adjacent to bladder
 - pneumaturia, fecaluria if colovesical fistula
- investigations
 - plain film x-ray
 - localized diverticulitis: ileus, thickened wall, small bowel obstruction, partial colonic obstruction
 - free air may be seen in 30% with perforation and generalized peritonitis
 - barium enema - contraindicated during an acute attack
 - risk chemical peritonitis
 - may interfere with subsequent investigations (colonoscopy) and treatment (anastomosis)
 - can use hypaque - water soluble
 - saw-tooth pattern (colonic spasm)
 - trickle of contrast out of colon
 - abscess cavities or sinus tracts
 - sigmoidoscopy/colonoscopy
 - not during an acute attack
 - mucosal edema, erythema → cannot advance scope
 - biopsy
 - CT scan
- treatment
 - conservative and medical (50% resolve)
 - localized (omentum has walled-off area)
 - NPO, IV, NG tube, and antibiotics (clindamycin, metronidazole)
 - analgesia
 - observe every 2-4 hours
 - surgical indications for diverticulitis
 - complications - sepsis (secondary to perforation, abscess), hemorrhage, fistula (vesical, vaginal, cutaneous), obstruction (extra-luminal abscess, chronic fibrosis)
 - recurrent inflammation, persistent pain or mass, right sided diverticulitis, age < 40, clinical deterioration within 48 hours, rule out cancer
 - surgical procedures
 - resection with colostomy and closure of distal rectal stump (Hartmann procedure), re-anastomosis 3 months later
 - sigmoidectomy and primary colorectal anastomosis is an alternative procedure



Drawings by Myra Rudakewich

ANGIODYSPLASIA

- intramural muscular hypertrophy --> submucosal venous obstruction
 - > focal submucosal venous dilatation and tortuosity
- most frequently in right colon of patients > 60 years old
- bleeding typically intermittent (melena, anemia, guaiac positive stools)
- diagnosis: colonoscopy (cherry red spots on mucosa), angiography (slow filling/early emptying mesenteric vein, vascular tuft), red cell technetium scan
- barium enema is contraindicated (obscures other x-rays, i.e. angiogram)
- treatment if symptomatic
 - electrocautery through colonoscope or right hemicolectomy with ileostomy (if bleeding persists or recurs)
 - endoscopic embolization (temporary, risk of colonic necrosis or perforation)

VOLVULUS

- rotation of segment of bowel about its mesentery
- 50% of patients > 70 years old and often bedridden
- symptoms due to bowel obstruction or bowel ischemia
- clinical presentation
 - sigmoid (65%)
 - intermittent crampy pains, obstipation and distension
 - cecal (30%) - congenital anomaly - cecum on mesentery rather than retroperitoneal
 - like distal SBO presentation: colicky pain, vomiting, obstipation +/- distension
- investigations
 - plain x-ray
 - "coffee-bean" shape of dilated bowel loop
 - concavity of "bean" points right for cecal volvulus, left for sigmoid
 - barium enema
 - "ace of spades" appearance due to contrast-filled lumen tapering of upper end of lower segment
- treatment
 - cecum
 - correct fluid and electrolyte imbalance
 - always operate - cecopexy (suture bowel to parietal peritoneum) or right colectomy with ileotransverse colonic anastomosis
 - sigmoid
 - operate (Hartmann procedure) if any evidence strangulation or perforation
 - otherwise - nonsurgical decompression (detort by flexible sigmoidoscope or barium enema and insert rectal tube past obstruction)
 - elective surgery recommended (recurrence = 50-70%)

COLORECTAL POLYPS

- clinical presentation
 - most asymptomatic
 - rectal bleeding, change in bowel habits
- prevalence: 30% at age 50, 40% at age 60, 50% at age 70
- pathology
 - benign lymphoid polyps
 - hamartomas
 - juvenile polyps
 - Peutz-Jegher's polyposis

- hyperplastic
 - asymptomatic
 - incidental finding on endoscopy
 - benign
- neoplastic
 - all premalignant
 - often carcinoma-in-situ
 - some have frank invasion into muscularis
 - adenomas

Table 5. Classification of Adenomatous Polyps

	Tubular	Tubulovillous	Villous
% of adenomas	65%	25%	10%
morphology	pedunculated	pedunculated	sessile
% carcinoma-in-situ or invasive cancer	15%	19%	25%

- increased risk of malignancy
 - all neoplastic polyps
 - size > 1 cm
 - villous (35%) vs. tubular (5%)
 - malignant polyp syndromes: familial polyposis
- diagnosis
 - 60% within reach of flexible sigmoidoscope, or colonoscopy and biopsy
- treatment
 - indications: symptoms, malignancy, or risk of malignancy
 - endoscopic removal of entire growth
 - surgical resection for those invading into muscularis and those too large to remove endoscopically
 - follow-up endoscopy 1 year later, then every 3-5 years
 - FAP - subtotal colectomy and ileorectal anastomosis or proctocolectomy +/- ileal pouch or ileostomy if many rectal polyps
 - HNPCC - subtotal colectomy and ileorectal anastomosis

COLORECTAL CARCINOMA

Younes Z., Johnson DA. Molecular and Genetic Advances in Gastrointestinal Cancer: State of the Art. *Digestive Diseases*. 1997;15(4-5):275-301

- epidemiology
 - third most common carcinoma (after skin and lung)
 - mean age = 70 years
 - 4% of colorectal carcinoma have synchronous lesions, therefore, investigate the whole colon
- risk factors
 - familial polyposis coli
 - adenomatous polyps
 - previous colorectal cancer
 - IBD
 - family history of colon cancer
 - age > 50
 - diet (increased fat, decreased fiber)
- pathogenesis
 - primary: ?, diet (low fibre, high fat), genetic
 - secondary: IBD (risk of cancer 1-2%/year if UC > 10 years, less risk if Crohn's)
- clinical presentation: see Table 6

Table 6. Clinical Presentation of Colorectal Carcinoma

	Right Colon	Left Colon	Rectum
Frequency	25% of cases	35% of cases	30% of cases
Pathology	large polypoid lesions that tend to bleed occultly	annular lesion (apple core) --> obstruction	ulcerating lesion
Symptoms	weight loss, weakness, R sided abdominal pain, obstruction rare	constipation +/- overflow, abdominal pain, diarrhea, "pencil" stools	obstruction, tenesmus
Signs	palpable RLQ mass (10%), iron deficiency anemia	gross bleeding	palpable mass on rectal exam, bright red rectal bleeding

- spread
 - direct extension
 - regional nodes (most common)
 - hematogenous: liver, lungs
 - transperitoneal spread: ovary
 - intraluminal
- diagnosis
 - sigmoidoscopy: 50% within reach
 - colonoscopy/air contrast barium enema (see Colour Atlas C6, C10)
 - metastatic work-up if no obvious metastases
 - labs: CBC, urinalysis, liver function tests, CEA, CXR
 - hemoccult
 - digital rectal exam (10% are palpable)
- staging (see Table 7)

Table 7. Duke-Astler-Coller Staging of Colorectal Carcinoma

Stage	Criteria	5 Year Survival
A	limited to mucosa	> 90%
B ₁	into muscularis propria	70-85%
B ₂	through muscularis propria	55-65%
C ₁	into muscularis propria with (+) nodes	45-55%
C ₂	through muscularis propria with (+) nodes	20-30%
D	distant metastases	< 1%

- treatment
 - surgery
 - for all cases
 - curative: wide resection of lesion with nodes and mesentery
 - palliative: if distant spread, then local control for hemorrhage or obstruction
 - 80% of recurrences occur within 2 years of resection
 - improved survival if metastasis consists of solitary hepatic mass that is resected
 - radiotherapy and chemotherapy
 - decrease recurrences only in rectal (Duke's B/C), not colon carcinoma
 - chemotherapy
 - 5-FU and levamisol or leucovorin (folinic acid) improve survival in Dukes C
- screening
 - CEA: not good for screening but appropriate to monitor for recurrence (increases before clinical findings); therefore, obtain pre and post-operative levels
 - annual digital rectal exam
 - sigmoidoscopy every 3-5 years in patients > 40 years

ILEOSTOMIES AND COLOSTOMIES

- ileostomies
 - Brooke: incontinent, continuous drainage
 - Koch: continent (no continuous drainage), increased complications
- colostomies
 - loop colostomy: an opening is created in a loop of bowel which is brought to the skin surface
 - end (terminal) colostomy the colon is divided and one end is brought out to the skin surface
- complications (20%)
 - obstruction: herniation, stenosis (skin and abdominal wall)
 - peri-ileostomy abscess and fistula
 - skin irritation
 - prolapse or retraction

HEMORRHOIDS

Etiology

- anal cushions, vascular and connective tissue complexes, become engorged forming hemorrhoids
- proposed causal factors
 - increased intra-abdominal pressure
 - chronic constipation
 - pregnancy
 - obesity

Classification and Management

- internal hemorrhoids
 - plexus of superior hemorrhoid veins --> portal circulation
 - engorged vascular cushions above dentate line usually seen at 3, 7, 11 o'clock positions --> when patient in lithotomy position
 - painless rectal bleeding, anemia, prolapse, mucus discharge, pruritis, burning pain
 - 1st degree: bleed but do not prolapse through the anus
 - high fibre/bulk diet, sitz baths, steroid cream, rubber band ligation, sclerotherapy, photocoagulation
 - 2nd degree: bleed but prolapse with straining, spontaneous reduction
 - rubber band ligation, photocoagulation
 - 3rd degree: bleed and prolapse requiring manual reduction
 - same as 2nd degree, may require closed hemorrhoidectomy
 - 4th degree: permanently prolapsed, cannot be manually reduced, bleeding
 - closed hemorrhoidectomy
- external hemorrhoids
 - plexus of inferior hemorrhoid veins --> systemic circulation
 - dilated venules below dentate line or perianal skin tags usually asymptomatic unless thrombosed, in which case they are very painful
 - usually present with pain after bowel movement
 - medical therapy: dietary fiber, stool softeners, avoid prolonged straining
 - thrombosed hemorrhoids resolve within 2 weeks
 - hemorrhoidectomy when patient presents within the first 48 hours of thrombosis, otherwise treat conservatively

ANAL FISSURES

- tear of anal canal sensitive squamous epithelium below dentate line
- 90% posterior midline, 10% anterior midline
- if off midline: IBD, STDs, TB, leukemia or anal carcinoma
- etiology
 - large, hard stools and irritant diarrheal stools
 - tightening of anal canal secondary to nervousness/pain
 - others: habitual use of cathartics, childbirth

Acute Fissure

- very painful bright red bleeding especially after bowel movement
- treatment is conservative: stool softeners, sitz baths

Chronic Fissure

- triad: fissure, sentinel skin tags, hypertrophied papillae
- treatment = surgery
 - objective is to relieve sphincter spasm --> increases blood flow and promotes healing
 - lateral subcutaneous internal sphincterotomy at 3 o'clock position

ANORECTAL ABSCESS

- bacterial infection of intersphincteric space starting from anal glands that empty into anal crypts
- E. Coli*, *Proteus*, *Streptococci*, *Staphylococci*, *Bacteriodes*, anaerobes
- abscess can spread vertically downward (perianal), vertically upward (supralelevator) or horizontally (ischioirectal)
- treatment: incision and drainage are curative in 50% of cases, 50% develop anorectal fistulas

Perianal Abscess

- unremitting pain, indurated swelling

Ischioirectal Abscess

- abscess in fatty fossa, can spread readily: necrotizing fasciitis, Fournier's gangrene
- pain, fever and leukocytosis prior to red, fluctuant mass

Suprlevator Abscess

- ❑ difficult to diagnose, rectal mass and swelling detectable with exam under anesthesia

FISTULA IN ANO

- ❑ usually associated with anorectal abscess; could indicate IBD
- ❑ an inflammatory tract with internal os at dentate line, external os on skin according to Goodsall's rule
- ❑ intermittent or constant purulent discharge from para-anal opening, pain
- ❑ palpable cord-like tract
- ❑ treatment
 - identify internal opening
 - fistulous tract identification (probing or fistulography) under anesthesia
 - unroof tract from external to internal opening, allow drainage
 - seton (thick suture) can be placed through tract
 - 1) promotes drainage
 - 2) promotes fibrosis and decreases incidence of incontinence
 - 3) delineates anatomy
 - post-op: sitz baths, irrigation and packing to ensure healing proceeds from inside to outside
- ❑ complications
 - recurrence, fecal incontinence

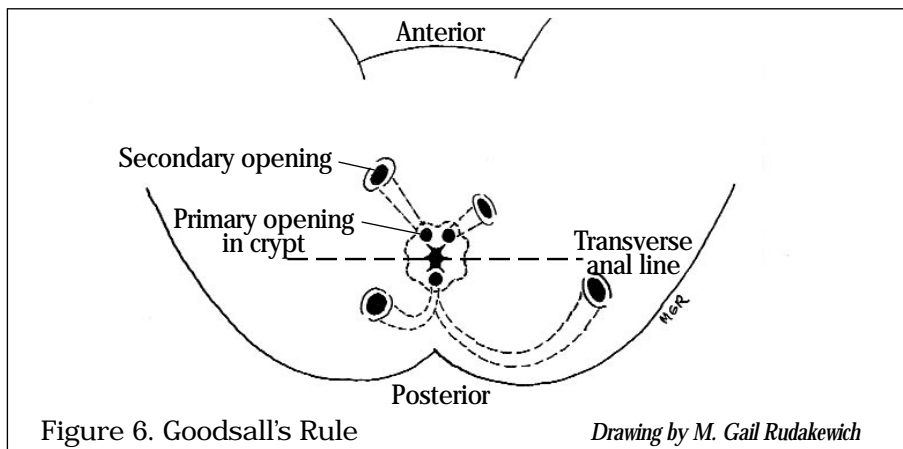


Figure 6. Goodsall's Rule

Drawing by M. Gail Rudakewich

PILONIDAL DISEASE

- ❑ acute abscess or chronic draining sinus in sacrococcygeal area usually asymptomatic until acutely infected
- ❑ develops secondary to obstruction of the hair follicles in this area --> leads to formation of cysts, sinuses or abscesses
- ❑ treatment
 - acute abscess - incision and drainage
 - chronic disease - pilonidal cystotomy or excision of sinus tract and cyst +/- marsupialization

RECTAL PROLAPSE

- ❑ protrusion of full thickness of rectum through anus that initially reduces spontaneously until continuously prolapsed. Must be differentiated from hemorrhoidal prolapse
- ❑ increased incidence in gynecological surgeries, chronic neurologic/psychiatric disorders affecting motility
- ❑ fecal and flatus incontinence secondary to dilated and weakened sphincter
- ❑ occurs in extremes of age
 - < 5 years old spontaneously resolve with conservative treatment (stool softeners)
 - > 40 years old usually require surgical treatment: anchoring rectum to sacrum (e.g. Ripstein procedure), excision of redundant rectum followed by colon anastomosis to lower rectum

ANAL NEOPLASMS

- ❑ epidermoid carcinoma of anal canal (above dentate line)
 - most common tumour of anal canal (75%)
 - squamous cell or transitional cell
 - presents with rectal pain, bleeding, mass
 - treatment of choice is chemotherapy, radiation +/- surgery with 80% 5 year survival
- ❑ malignant melanoma of anal margin
 - 3rd most common site after skin, eyes
 - aggressive, distant metastases are common at time of diagnosis
 - early radical surgery is treatment of choice
 - < 15% 5 year survival

- ❑ protrusion of a viscus into an area in which it is not normally contained
- ❑ incidence
 - male:female = 9:1
 - lifetime risk of developing hernia
 - males 5%
 - females 1%
 - most common surgical disease of males
- ❑ general types
 - internal hernia - sac is within abdominal cavity
 - external hernia - sac protrudes completely through abdominal wall
 - strangulated hernia - vascular supply of protruded viscus is compromised
 - incarcerated hernia - irreducible hernia, not necessarily strangulated
 - Richter's hernia - contents of the sac consist of only one side of intestinal wall (usually antimesenteric)
 - sliding hernia - part of wall of hernia formed by protruding viscus (usually cecum or sigmoid colon)

Locations and Anatomy

- ❑ borders of Hasselbach's triangle - lateral edge of rectus sheath, inguinal ligament, inferior epigastric vessels
- ❑ inguinal
 - tends to affect males > females, but remains most common hernia in women
 - indirect
 - etiology
 - persistent processus in 20% of adults
 - anatomy
 - originates in deep inguinal ring
 - lateral to inferior epigastric artery
 - often descends into scrotal sac
 - complications
 - incarceration, strangulation
 - direct
 - etiology
 - acquired weakness in floor of Hesselbach's triangle (transversalis fascia)
 - due to wear/tear, combined with increased intra-abdominal pressure
 - anatomy
 - through Hesselbach's triangle
 - medial to inferior epigastric artery
 - often do not descend into scrotal sac
 - complications
 - incarceration rare
 - pantaloon
 - combined direct and indirect hernias
 - peritoneum draped over inferior epigastric vessels
- ❑ femoral
 - epidemiology
 - affects mostly females
 - anatomy
 - into femoral canal, below inguinal ligament but may override it
 - located medial to femoral vein
 - complications
 - tendency to strangulate since it has a narrow neck
- ❑ other
 - incisional: ventral hernias - hernia at site of wound closure
 - umbilical: usually congenital, passes through umbilical ring
 - epigastric: defect in linea alba above umbilicus
 - obturator: through obturator foramen
 - spigelian: ventral hernia through defect in linea semilunaris
 - lumbar: defect in posterior abdominal wall; superior - Grynfeltt's, inferior - Petit's

- clinical presentation
 - contributing factors
 - obesity, chronic cough, pregnancy, constipation, straining on urination, ascites, activities which increase intra-abdominal pressure
 - previous hernia repair
 - groin mass of variable size
 - develops insidiously in most cases
 - occasionally precipitated by single forceful muscular event
 - associated discomfort
 - worse at end of day
 - relieved at night when patient reclines and hernia reduces
 - relieved with manual reduction
 - +/- obstruction
 - +/- local tenderness
 - must examine patient in both supine and standing positions
 - hernial sac and contents enlarge and transmit palpable impulse when patient coughs or strains
 - may auscultate bowel sounds
 - unable to “get above” groin mass with palpation
 - mass does not transilluminate
 - strangulation results in
 - intense pain followed by tenderness
 - intestinal obstruction
 - gangrenous bowel
 - sepsis
 - a surgical emergency
 - small, new hernias more likely to strangulate
 - do not attempt to manually reduce hernia if sepsis present or contents of hernial sac thought to be gangrenous
- treatment
 - surgical: goals are to prevent strangulation, eviscerations and for cosmetics
 - indirect hernias - principle of repair is high ligation of sac and tightening of the internal ring
 - direct hernias - principle of repair is to rebuild Hesselbach's triangle: need good fascia or a prosthesis
 - femoral hernias - principle of repair is to remove sac of fat and close the femoral canal with sutures
- postoperative complications
 - scrotal hematoma
 - deep bleeding - may enter retroperitoneal space and not be initially apparent
 - difficulty voiding
 - painful scrotal swelling from compromised venous return of testes
 - neuroma/neuritis
 - stenosis/occlusion of femoral vein when treating femoral hernias causing acute leg swelling
- prognosis (inguinal hernia repair)
 - indirect: < 1% risk of recurrence
 - direct: 3-4% risk of recurrence

LIVER CYSTS

- normally asymptomatic
- if large → upper abdominal discomfort/mass

Parasitic Liver Cysts

- hydatid disease (tapeworm)
 - infection with parasite *Echinococcus granulosus*
 - endemic Southern Europe, Middle East, Australia, South America
 - *Echinococcus granulosus* passed by fecal/oral route in cows, sheep, moose, caribou or humans
 - secondary infection with tender hepatomegaly, fever, chills
 - asymptomatic mass (most often) or chronic pain, hepatomegaly
 - rupture into biliary tree → biliary colic, jaundice or anaphylaxis
 - diagnosis
 - Casoni skin test (risk anaphylaxis)
 - complement fixation - best
 - presence of mass, often calcified, on U/S or CT
 - treatment
 - medical - albendazole
 - surgical - remove cyst (spillage of antigenic contents into peritoneal cavity can cause anaphylaxis) and omentoplasty

Non-Parasitic Liver Cysts

- simple cyst
- multicystic (50% have polycystic kidney; 33% of patients with autosomal dominant polycystic kidney disease have liver cysts)
- choledochal cyst
 - congenital malformations of pancreaticobiliary tree
 - 4 types with the extreme form called Caroli's disease (multiple cystic dilations in intrahepatic ducts)
 - signs and symptoms include recurrent abdominal pain, intermittent jaundice, RUQ mass
 - 30% pain, jaundice, abdominal mass
 - diagnosis - U/S, transhepatic cholangiography, LFTs
 - treatment is surgical (extent of resection depends on type of cyst) - liver transplant indicated if cyst involvement of intrahepatic bile ducts (Caroli's disease)
 - complications of chronic disease are biliary cirrhosis, portal hypertension, bile duct carcinoma
- neoplastic
 - cystadenoma; premalignant, usually require resection
 - cystadenocarcinoma

LIVER ABSCESSSES

Bacterial Liver Abscess

- most common hepatic abscess in Western world
- usually secondary to suppurative process in abdomen
 - cholangitis, appendicitis, diverticulitis, generalized sepsis, also seeding from endocarditis
- organism related to primary source
 - abdominal - Gram -ve rods (*E. coli*), anaerobes (*Bacteroides*), *Enterococcus*
 - extra-abdominal - Gram +ve organisms (e.g. from bacterial endocarditis, pneumonitis)
- 25% have no antecedent infection = cryptogenic infection
- usually present with fever, malaise, chills, anorexia, weight loss, abdominal pain or nausea with right upper quadrant (RUQ) tenderness, hepatomegaly, jaundice, and pleural dullness to percussion
- lab - leukocytosis, anemia, elevated LFTs
- diagnosis
 - U/S, CXR (R basilar atelectasis/effusion), CT, serum antibody titre, percutaneous aspiration and drainage
 - more common in right lobe

- treatment
 - treat underlying cause
 - surgical drainage and IV antibiotics
- overall mortality 15% - higher rate if delay in diagnosis, multiple abscesses, malnutrition

Amoebic Abscess

- follows intestinal manifestation by *Entamoeba histolytica* via contaminated drinking water, food, person-to-person
- associated with fever, leukocytosis, diarrhea, RUQ pain, hepatomegaly
- often a single large cavity in the right lobe (90%)
- treatment: parenteral antibiotics (metronidazole), aspiration of abscess if large; surgical drainage indicated if complications arise (rupture)

NEOPLASMS

Benign Liver Neoplasms

- hemangioma (cavernous)
 - most common benign hepatic tumour; results from malformation of angioblastic fetal tissue
 - female:male = 6:1 associated with OCP use
 - usually no treatment, unless tumour bleeds or is symptomatic (excision by lobectomy or enucleation)
 - can cause abdominal pain (compression of nearby structures, expansion) or form palpable mass if > 4 cm
 - arteriography is diagnostic, but red blood cell scan as useful and cheaper
 - do not biopsy --> massive hemorrhage
- adenoma
 - benign glandular epithelial tumour
 - young women on birth control pill (BCP) for many years
 - 25% present with RUQ pain or mass
 - up to 30% present with hemorrhage into peritoneal cavity
 - malignant potential
 - diagnosis: mass on U/S or CT
 - treatment
 - stop BCP or anabolic steroids
 - excise especially if large due to increased risk of malignancy and spontaneous rupture/hemorrhage
- focal nodular hyperplasia (FNH, hamartoma, benign)
 - female:male = 2:1 (in age 40 on average)
 - rarely grow or bleed
 - "central stellate scar" on CT scan
 - treatment: resect only if symptomatic

Malignant Liver Neoplasms

- primary
 - usually hepatocellular adenocarcinoma (hepatoma)
 - uncommon in North America, but 20-25% of all carcinomas in the Orient and Africa
 - male:female=2:1
 - risk factors
 - chronic hepatitis B and C infections
 - cirrhosis (especially macronodular)
 - BCP's - 3x increased risk
 - steroids
 - smoking, alcohol
 - chemical carcinogens (aflatoxin, vinyl chloride - associated with angiosarcoma)
 - parasite infection (*Clonorchis sinensis* associated with cholangiocarcinoma)
 - hemochromatosis, α -1-antitrypsin deficiency
 - pathogenesis of hepatocellular carcinoma with hepatitis B presumably involves integrated HBV-DNA that acts as a cancer promoter
 - signs and symptoms
 - RUQ discomfort, right shoulder pain
 - jaundice in 1/3, weakness, weight loss, fever
 - hepatomegaly, bruit, rub
 - 10-15% ascites with blood (sudden intra-abdominal hemorrhage)
 - paraneoplastic Cushing's syndrome
 - diagnosis
 - elevated alkaline phosphatase, bilirubin, and α -feto-protein (80% of patients)

- imaging: U/S (best), liver scan, CT, MRI, angiography
- biopsy
- treatment
 - cirrhosis relative contraindication to tumour resection due to decreased hepatic reserve
 - surgery - 10% of patients have resectable tumours
 - liver transplant (not if Hep B)
 - percutaneous ethanol injection
 - cryotherapy
 - chemotherapy - systemic or hepatic arterial infusion
- prognosis
 - 70% have mets to nodes and lung
 - 5 year survival of all patients - 5%
 - 3 month survival if no treatment
 - 5 year survival of patients undergoing complete resection - 11-40%
 - other types: cholangiocarcinoma (7%), angiosarcoma, hepatoblastoma (children)
- secondary (20 x more common than primary)
 - metastases to the liver
 - 25-50% of people with cancer at autopsy have liver metastases
 - bronchogenic (most common), GI, pancreas, breast, ovary, uterus, kidney
 - treatment
 - hepatic resection if control of primary is possible, no extrahepatic mets and < 4 lesions
 - cryotherapy
 - possibly chemotherapy
 - 5 year overall survival 20-50% with resection of colorectal mets (overall survival with colorectal metastases to liver approximately 6-7 months)

PORTAL HYPERTENSION (see Gastroenterology Notes)

Table 8. Child's Classification for Determining Operative Risk for Shunting Procedure in Portal Hypertension

	A	B	C
Serum bilirubin (mg/dL)	< 2	2-3	> 3
Serum albumin (g/dL)	> 3.5	3-3.5	< 3
Presence of ascites	absent	controllable	refractory
Encephalopathy	absent	minimal	severe
Malnutrition	absent	mild	severe
Operative mortality	2%	10%	50%

Surgical Management of Bleeding Varices in Portal Hypertension

- indications
 - bleeding continues despite transfusion of blood (5 units) within 24 hours
- sclerotherapy - usually treatment of choice (90% effective); +/- vasopressin, NTG, somatostatin, propranolol with 20-30% mortality
- balloon tamponade (Blakemore tube)
 - 12-24 hours: 75% effective initially (20-50% rebleed rate)
 - risk of aspiration, ulceration, asphyxiation, or rupture; therefore oro/nasotracheal intubation indicated
- transjugular intrahepatic porto-systemic shunt (TIPSS)

Shunting Procedures to Decrease Portal Venous Pressure

- portal decompression
 - operative mortality: Child's A 0-5%, B 5-15%, C 20-50%
 - nonselective shunts: direct all portal blood flow away from liver
 - portocaval (end-to-side and side-to-side anastomoses)
 - direct anastomosis between IVC and portal vein
 - used in acute bleeding/ascites
 - very effective (> 90%), low re-bleed
 - risk of hepatic encephalopathy high (11-38%); hepatic failure (13-18%) due to low portal flow from shunt
 - distal spleno-renal (Warren)
 - anastomosis of splenic vein to left renal vein

- procedure of choice for elective shunt surgery
- not used in patients with ascites
- decreased rate of hepatic encephalopathy and failure as portal flow and liver detoxification partially intact
- transjugular intravascular portasystemic shunt (TIPSS)
 - new technique performed by radiologists
 - creates a shunt between portal and hepatic vein via a catheter placed in the liver
 - can be used to stop acute bleeding or prevent rebleeding
 - shunt usually remains open up to one year
- liver transplant
 - 70% 5 year survival in non-alcoholic cirrhotic

Ascites

- management
 - portocaval shunt (side to side)
 - peritoneovenous shunt: drainage of intraperitoneal fluid to vascular compartment (i.e. Leveen shunt)
 - indications: failure of medical treatment, encephalopathy, azotemia

Hypersplenism

- treated conservatively
- splenectomy or Warren shunt if severe or development of splenic vein thrombosis

LIVER TRANSPLANTATION

- indications: end-stage complications (refractory ascites, encephalopathy and bleeding varices)

Candidacy for Transplantation

- parenchymal disease
 - post-necrotic cirrhosis (chronic active hepatitis)
 - alcoholic cirrhosis
 - acute liver failure
 - Budd-Chiari syndrome
 - congenital hepatic fibrosis
 - cystic fibrosis
- cholestatic disease
 - biliary atresia
 - primary biliary cirrhosis
 - sclerosing cholangitis
- inborn errors of metabolism
 - α -1-anti-trypsin deficiency
 - Wilson's disease
- tumours
 - primary malignant
 - benign

Procedure

- duration 6-10 hours
- involves external venovenous bypass, venous anastomoses, reperfusion of new liver, hemostasis and reconstruction of biliary tract (Roux-en-Y) or end-to-end anastomosis

Post-op Complications

- surgical - hepatic artery thrombosis, associated with anastomosis between donor and recipient
- acute and chronic rejection
- post-transplant death (MOSF)
- recurrence of hepatitis B

Survival

- pediatric 78% 1 year, 74% 5 years
- adult 76% 1 year, 63% 5 years

CHOLELITHIASIS

Pathogenesis

- imbalance of cholesterol and its solubilizing agents, bile salts and lecithin concentrations
- if hepatic cholesterol secretion is excessive then bile salts and lecithin are "overloaded", supersaturated cholesterol precipitates and can form gallstones

Types of Stones

- cholesterol (80%) = mixed (> 70% cholesterol by weight)
 - risk factors
 - female, fat, fertile, forties
 - North American Indians highest incidence
 - prolonged fasting + total parenteral nutrition (TPN; usually results in acute acalculous cholecystitis)
 - rapid weight loss
 - terminal ileal resection or disease (e.g. inflammatory bowel disease)
- pigment stones (20%)
 - smooth green/black to brown: composed of unconjugated bilirubin, calcium, bile acids
 - black pigment stones
 - associated with cirrhosis, chronic hemolytic states
 - calcium bilirubinate stones
 - associated with bile stasis, (biliary strictures, dilatation and biliary infection (*Clonorchis sinensis*))

Natural History

- 80% are asymptomatic
- 18% develop symptoms over 15 years

Clinical Presentation (in severity of increasing order)

- asymptomatic stones
 - most asymptomatic gallstones do NOT require treatment
 - consider operating if calcified "porcelain" gallbladder (15-20% associated cancer), diabetes, history of biliary pancreatitis
- biliary colic
- cholecystitis - acute and chronic
- complications of cholecystitis
- choledocholithiasis (CBD stones)

BILIARY COLIC (or CHRONIC CHOLECYSTITIS)

- many patients with acute cholecystitis have a history of episodic biliary colic
- mechanism: gallstone temporarily impacted in cystic duct, no infection
- signs and symptoms
 - steady pain (not colic) in epigastrium or RUQ for minutes to hours
 - frequently occurs at night or after fatty meal
 - can radiate to right shoulder or scapula
 - associated nausea/vomiting
 - no peritoneal findings
 - no systemic signs
- differential diagnosis - pancreatitis, PUD, hiatus hernia with reflux, gastritis
- diagnostic investigation
 - normal blood work
 - U/S shows gallstones
- treatment
 - elective cholecystectomy (95% success)

ACUTE CHOLECYSTITIS

- mechanism
 - inflammation of gallbladder resulting from obstruction of cystic duct by gallstone (80%)
 - no cholelithiasis in 20% (acalculous - see below)

- ❑ signs and symptoms
 - severe constant epigastric or RUQ pain
 - systemic signs - fever, tachycardia
 - focal peritoneal findings - Murphy's sign (sudden cessation of inspiration with deep RUQ palpation)
 - palpable gallbladder in one third of patients
- ❑ differential diagnosis
 - perforated or penetrating peptic ulcer
 - myocardial infarction
 - pancreatitis
 - hiatus hernia
 - right lower lobe pneumonia
 - appendicitis
 - hepatitis
 - herpes zoster
- ❑ diagnostic investigation
 - elevated WBC, left shift
 - mildly elevated bilirubin, ALP
 - sometimes slight elevation AST, ALT
 - U/S shows distended, edematous gallbladder, pericholecystic fluid, large stone stuck in gallbladder neck, sonographic Murphy's sign
- ❑ complications
 - hydrops: mucus accumulation in gallbladder due to cystic duct obstruction; may lead to necrosis
 - gangrene and perforation: may cause localized abscess or generalized peritonitis (can occur 3 days after onset)
 - empyema of gallbladder (suppurative cholangitis)
 - cholecystoenteric fistula from repeated attacks of cholecystitis
 - gallstone ileus (see below)
 - choledocholithiasis - 15% of patients with gallstones
- ❑ mortality 5%
- ❑ treatment
 - admit, hydrate, NG tube, antibiotics if high risk (elderly, immunosuppressed)
 - lack of improvement with conservative treatment --> operate within 24-48 hours (cholecystectomy)
 - earlier O.R. if high risk (DM, steroids) or severe disease
 - cholecystostomy tube if general anesthetic contraindicated

COMPLICATIONS OF CHOLECYSTECTOMY

- ❑ general
 - anesthetic risk
 - post-op complications (see Surgical Complications Section)
- ❑ specific
 - bile duct injury (0.2-1%)
 - correct with Roux-en-Y choledochojejunostomy

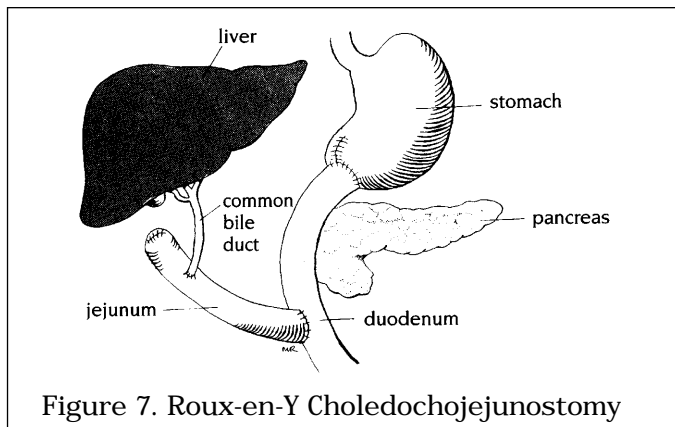


Figure 7. Roux-en-Y Choledochojejunostomy

Drawings by Myra Rudakewich

ACALCULOUS CHOLECYSTITIS

- acute or chronic cholecystitis in the absence of stones
- usually diabetic, immunosuppressed or post-op
- etiology
 - dehydration
 - systemic disease (e.g. MOSF)
 - generalized sepsis
 - kinking or fibrosis of the gallbladder
 - thrombosis of the cystic artery
 - sphincter spasm with obstruction of the biliary and pancreatic ducts
 - prolonged fasting
 - collagen vascular disease
- treatment
 - cholecystectomy or cholecystostomy

GALLSTONE PANCREATITIS

- mechanism: gallstone impacted in common pancreatic duct
- signs and symptoms
 - epigastric, back pain
- diagnostic investigation
 - high amylase, lipase
 - high liver enzymes
 - most cases mild Ranson's criteria
 - U/S may show multiple stones (may have passed spontaneously), edematous pancreas
 - CT if severe to evaluate for complications
- treatment
 - supportive
 - cholecystectomy during same admission after acute attack subsided

GALLSTONE ILEUS

- mechanism - cholecystoenteric fistula (usually duodenal) with large gallstone impacting most commonly at the ileocecal valve
- not an ileus, but a true partial or complete small bowel obstruction
- clinical presentation
 - crampy abdominal pain, nausea, vomiting
- diagnostic investigation
 - 3 views abdomen shows dilated small intestine, gallstone in RLQ and air in biliary tree (15%)
 - upper GI if unclear
- treatment
 - hydrate, operate to remove stone; (enterotomy) usually don't have to remove gallbladder (30% cholecystectomy)
 - only if chronic symptoms
 - fistula usually closes spontaneously
- mortality 10-15%

DIAGNOSTIC EVALUATION OF BILIARY TREE

- U/S is diagnostic procedure of choice
- oral cholecystography
 - opaque drug taken night before, look for filling defect (stones)
 - failure of gallbladder to opacify indicative of complete obstruction by stone or unable to concentrate because of inflammation
- HIDA scan
 - radioisotope technetium excreted in high concentrations in bile
 - highly suggestive of acute cholecystitis when gallbladder not visualized due to cystic duct obstruction 4 hours after injection
 - reliable when bilirubin > 20
- PTC
 - injection of contrast via needle passed through hepatic parenchyma
 - useful for proximal bile duct lesions or when ERCP fails
 - antibiotic premedication always, contraindicated with cholangitis

- ❑ ERCP
 - opacification of bile and pancreatic ducts possible
 - preferred method to demonstrate CBD stones and periampullary region

CHOLEDOCHOLITHIASIS

- ❑ stones in common bile duct
- ❑ signs and symptoms
 - 50% asymptomatic
 - tenderness in RUQ or epigastrium
 - biliary pain with intermittent chills, fever or fluctuating jaundice
 - episodic cholangitis
 - spectrum from healthy to icterus, toxicity, high fever and chills
- ❑ diagnostic investigations
 - increased bilirubin (<10), ALP
 - leukocytosis often > 20 x 10⁹/L
 - U/S - duct dilatation, does not detect CBD stones
 - ERCP (if no previous cholecystectomy) otherwise PTC appropriate
- ❑ treatment
 - antibiotics, NG tube, IV hydration
 - if no improvement in 2-4 days then ERCP/PTC+sphincterotomy or surgery with CBD exploration and laparoscopic cholecystectomy

ACUTE CHOLANGITIS

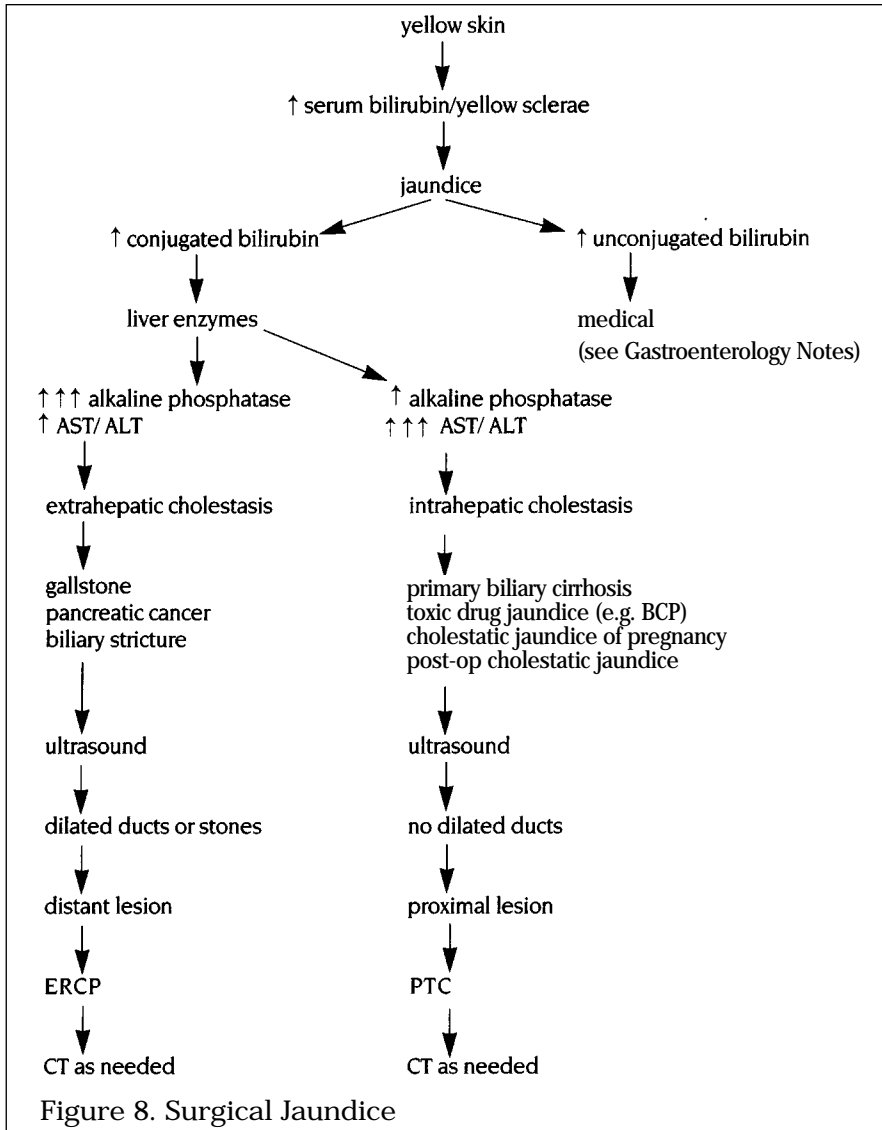
- ❑ mechanism: obstruction of common bile duct leading to biliary stasis, bacterial overgrowth, suppuration, and biliary sepsis - life threatening
- ❑ etiology
 - choledocholithiasis (60%)
 - post-operative stricture
 - pancreatic or biliary neoplasms
- ❑ organisms: *E. coli*, *Klebsiella*, *Pseudomonas*, *Enterococci*, *B. fragilis*, *Proteus*
- ❑ signs and symptoms
 - Charcot's triad: fever, jaundice, RUQ pain
 - Reynold's pentad: Charcot's triad + mental confusion, hypotension leading to renal failure
- ❑ diagnostic investigations
 - elevated WBC
 - elevated liver function tests and conjugated bilirubin
 - U/S shows gallstones in gallbladder +/- stones seen in bile ducts (approximately 10-15%) +/- dilated extrahepatic or intrahepatic bile ducts
- ❑ treatment
 - antibiotics, hydration
 - urgent ERCP - diagnostic and therapeutic with papillotomy to remove stones
 - if ERCP unavailable or unsuccessful, then PTC
 - if ERCP, PTC unavailable, surgery to decompress CBD ---> T-tube
 - if elderly, (usually) don't have to remove gallbladder if adequate ERCP + papillotomy

CARCINOMA OF THE BILE DUCT

- ❑ majority adenocarcinoma
- ❑ 2% of cancer deaths (1/8 as common as pancreatic cancer)
- ❑ associations
 - age 50-70 years
 - age 20-40 if chronic ulcerative colitis, Clonorchis sinensis infestation, sclerosing cholangitis, choledochal cysts
 - female:male = 2:1
- ❑ clinical presentation
 - local: RUQ pain, palpable mass (if tumour in CBD)
 - systemic: unremitting jaundice, pruritus, weight loss, anorexia
- ❑ investigations
 - Klatskin tumour (at common hepatic duct bifurcation) causes increased ALP, bilirubin, but normal AST
- ❑ diagnosis: U/S and CT (dilated bile ducts), ERCP and PTC (depict tumour)
- ❑ treatment
 - +/- stents for palliation
 - radiation or Whipple's if tumour at low end of CBD

- prognosis
 - spread: growth into portal vein or hepatic artery, liver, hilar nodes
 - 10-15% 5 year survival
 - death results from progressive biliary cirrhosis, persistent intrahepatic infection and abscess formation, or sepsis

JAUNDICE



ACUTE PANCREATITIS (see Gastroenterology Notes)

- ❑ usually no surgical management in uncomplicated acute pancreatitis
- ❑ surgical indications in acute pancreatitis
 - secondary pancreatic infections - abscess, infected pseudocysts/necrosis
 - gallstone-associated pancreatitis
 - uncertainty of clinical diagnosis
 - worsening clinical condition despite optimal supportive care
- ❑ complications
 - pseudocyst (2-10%)
 - collection of pancreatic secretions in a cyst lacking true epithelium
 - risk of rupture, hemorrhage and infection (rare)
 - 2-3 weeks post-attack: persistent pain, fever, ileus, mass, nausea/vomiting, early satiety, persistent elevation of amylase
 - 40% resolve spontaneously within 6-12 weeks (keep NPO and on TPN)
 - diagnosis: clinical, U/S, CT
 - treatment: internal (preferred) or external drainage (latter if infected or sick patient) once pseudocyst matures
 - biopsy to rule out malignancy
 - recurrence rate 10%
 - abscess (5%)
 - 1-4 weeks post-attack: fever, toxic, abdominal pain, distention
 - diagnosis: increased amylase, increased AST/ALT (50%), elevated WBC, CT (fluid and gas)
 - high mortality - requires extensive surgical debridement and broad-spectrum antibiotics
 - ascites
 - secondary to pseudocyst disruption (common) or direct pancreatic duct disruption
 - diagnose by paracentesis: high amylase, high protein
 - treatment: NPO, TPN 2-3 weeks, somatostatin
 - ERCP if not resolved to determine anatomy; Rou-en-Y jejunostomy to site of leak
 - necrosis
 - diagnosis by CT
 - treatment: debridement
 - hemorrhage
 - erosion of arterial pseudoaneurysm secondary to pseudocyst, abscess, or necrotizing pancreatitis
 - clinical presentation: increased abdominal mass, abdominal pain, hypotension
 - diagnosis: angiography
 - treatment: immediate surgery
 - sepsis
 - MOSF
- ❑ prognosis of all complications
 - 80% improve rapidly
 - 20% have at least one complication from which 1/3 die

CHRONIC PANCREATITIS (see Gastroenterology Notes)

(see Colour Atlas C7)

- ❑ surgical treatment
 - indications for surgical treatment: debilitating abdominal pain, CBD obstruction, duodenal obstruction, persistent pseudocyst
 - ERCP for planning surgical management - dilated ducts with areas of stricture (chain of lakes)
 - drainage procedure if ducts > 8 mm
 - Puestow (longitudinal pancreatico-jejunostomy)
 - 80-90% have pain relief, but 5 years post-op only 50-60% remain pain-free
 - Whipple (pancreaticoduodenectomy) 80% have pain relief
 - pancreatectomy
 - use when no dilated ducts
 - amount of resection depends on disease focus (i.e. limited vs. subtotal vs. total pancreatectomy)
 - do not percutaneously access a pseudocyst unless immediate drainage of infection required. Goal is to allow wall of pseudocyst to mature (3-4 weeks) followed by internal drainage through stomach

PANCREATIC CANCER

- epidemiology
 - fifth most common cause of cancer death
 - African descent at increased risk
 - male:female = 1.7:1
 - age (average 50-70)
- risk factors
 - increased age
 - smoking - 2-5x increased risk
 - high fat/low fibre diets
 - chronic pancreatitis
 - diabetes
 - heavy alcohol use
 - chemical: betanaphthylamine, benzidine
- clinical presentation is related to location of tumour
 - head of the pancreas (70%)
 - weight loss, painless obstructive jaundice
 - palpable tumour mass = incurable
 - Courvoisier's sign = palpable non-tender gall bladder in jaundiced patient suggesting malignant common bile duct obstruction
 - Courvoisier's Law = a palpably distended, non tender gallbladder is unlikely to be due to cholelithiasis
 - carcinoma of body or tail of pancreas (30%)
 - tends to present later and usually inoperable
 - < 10% jaundiced
 - weight loss, vague midepigastric pain
 - sudden onset diabetes mellitus
- surgical dictum: vague abdominal pain with weight loss +/- jaundice in a patient > 50 years old is pancreatic cancer until proven otherwise
- diagnosis
 - serum chemistry non-specific: elevated ALP and bilirubin (>18)
 - evidence of obstruction: U/S, ERCP (best), PTC, CT
 - beware of TB, lymphoma
 - these are not treated surgically
- pathology
 - ductal adenocarcinoma - most common type (75-80%)
 - giant cell carcinoma (4%)
 - adenosquamous carcinoma (3%)
 - other: mucinous, cystadenocarcinoma, acinar cell carcinoma
- spread
 - early to local lymph nodes and liver
- treatment
 - operable (i.e. no metastases outside abdomen, liver, or peritoneal structures, and no involvement of porta hepatis, superior mesenteric artery, portal vein at body of pancreas)
 - 20% of head of pancreas cancers can be resected
 - Whipple's procedure (pancreatoduodenectomy) for cure - 5% mortality
 - distal pancreatectomy +/- splenectomy, lymphadenectomy if carcinoma of midbody and tail of pancreas
 - inoperable (i.e. involves liver, vasculature or regional nodes)
 - most body and tail cancers not resectable
 - relieve biliary/duodenal obstruction with endoscopic stenting or double bypass procedure: choledochoenterostomy, gastroenterostomy
 - palliative pain control
 - combination chemotherapy/radiotherapy for palliation, increased medical survival post-surgery
- prognosis
 - average survival - 7 months
 - 5 year survival is 10%
 - following Whipple's procedure, mean survival - 18 months
 - if resection margins clear and no tumour spread, then 5 year survival for ampullary carcinoma 30%, pancreatic carcinoma 20%
 - most important prognostic indicator is lymph node status

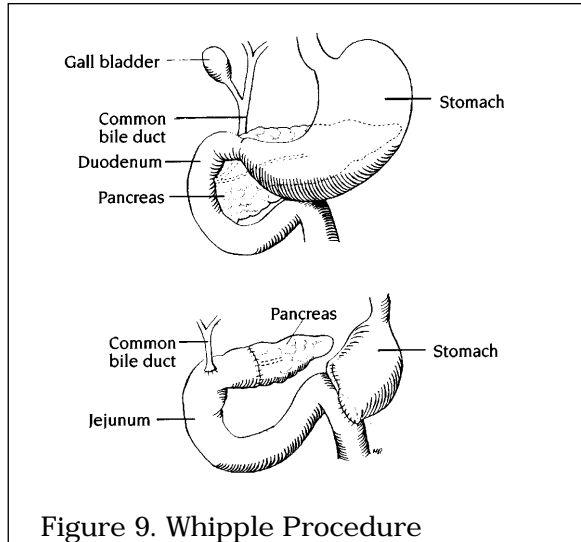


Figure 9. Whipple Procedure

Drawings by Myra Rudakewich

SPLEEN

HYPERSPLENISM (see Hematology Notes)

- ❑ exaggeration of normal splenic functions such as removal and destruction of aged/defective RBC, sequestration of normal cells and production of immunoglobulins
- ❑ etiology
 - primary hypersplenism
 - rare
 - diagnosis of exclusion
 - secondary hypersplenism
 - congestion (most common) secondary to portal hypertension
 - neoplasia- lymphoma, leukemia, myeloid metaplasia
 - infections - EBV, TB
 - inflammatory diseases - sarcoid, rheumatoid arthritis
 - hematologic - spherocytosis, G6PD deficiency
 - storage diseases - Gaucher's disease, amyloid
- ❑ clinical presentation
 - +/- LUQ fullness, discomfort, spontaneous rupture
 - anemia, leukopenia, thrombocytopenia
- ❑ diagnosis
 - CBC, differential and smear, Hb electrophoresis
 - bone marrow biopsy
 - splenic function tests: radiolabeled RBC/platelets (measure rate of disappearance)
- ❑ treatment
 - splenectomy
 - reduces number of transfusions, number of infections, prevents hemorrhage, and decreases pain

SPLENECTOMY

- ❑ indications
 - always
 - primary splenic tumour (rare)
 - hereditary spherocytosis
 - usually
 - primary hypersplenism
 - chronic immune thrombocytopenia purpura
 - splenic vein thrombosis causing esophageal varices
 - splenic abscess

- sometimes
 - splenic injury (most common reason for splenectomy)
- complications
 - short term
 - atelectasis of the left lower lung
 - injury to surrounding structures e.g. gastric wall, tail of pancreas
 - post-op hemorrhage
 - post-op thrombocytosis, leukocytosis
 - subphrenic abscess
 - long term
 - post-splenectomy sepsis (encapsulated organisms)
 - 4% of splenectomized patients
 - 50% fatality
- prophylaxis
 - vaccinations: pneumococcal, *Haemophilus influenzae*
 - penicillin for children < 18 years old

FISTULA

- abnormal communication between two epithelialized surfaces
- etiology
 - foreign object erosion (e.g. gallstone, graft)
 - infection
 - IBD (especially Crohn's disease)
 - congenital
 - trauma
 - iatrogenic
- why fistulas stay open (FRIENDO)
 - Foreign body
 - Radiation
 - Infection
 - Epithelialization
 - Neoplasm
 - Distal obstruction (most common)
 - Others: increased flow; steroids (may inhibit closure, but usually will not maintain fistula)
- bowel fistula management
 - relieve obstruction
 - fluid and electrolyte balance
 - nutrition - elemental/low residue
 - decrease flow - NPO, TPN
 - decrease secretion - octreotide/somatostatin
 - skin care (enterocutaneous fistula - proteolytic enzymes)
 - identify anatomy - fistulogram
 - surgical intervention dependent upon etiology, or uncertainty of diagnosis

BREAST

FIBROCYSTIC DISEASE

- benign breast condition consisting of fibrous and cystic changes in breast
- age 30-50 years
- pain with multiple bilateral lumps
- fluctuate in size and tenderness with menstrual cycle
- if no dominant mass, observe to ensure no mass dominates
- for a dominant mass, Fine Needle Aspiration (see below)
- if > 40 years, mammography every 3 years

FIBROADENOMA

- most common benign breast tumour in women
- no malignant potential
- usually age < 30 years
- smooth, rubbery, discrete nodule, non-tender, mobile
- usually excised to confirm diagnosis

FAT NECROSIS

- due to trauma (although positive history in only 50%)
- firm, ill-defined mass with skin or nipple retraction
- +/- tenderness
- will regress on own but complete excisional biopsy the safest approach to rule out carcinoma

PAPILLOMA

- solitary intraductal benign polyp
- most common cause of bloody nipple discharge

DIFFERENTIAL DIAGNOSIS OF NIPPLE DISCHARGE

- bloody - papilloma, papillary/intraductal carcinoma, Paget's, fibrocystic change
- serous - duct hyperplasia, pregnancy, BCP, menses, cancer
- green/brown - mamillary duct ectasia, fibrocystic change
- purulent - abscess
- milky - postlactation, BCP, prolactinoma

MASTITIS

- nursing mothers; sporadic or epidemic
- etiologic agent: *S. aureus*
- unilateral localized pain, tenderness and erythema
- sporadic: acinar and duct systems uninvolved, therefore, infant should continue being nursed
- recurrent: due to regurgitation of milk back into ducts, therefore, discontinue nursing and suppress lactation
- antibiotic therapy: if start delayed > 24 hours, increased risk of abscess requiring incision and drainage

BREAST CANCER

- epidemiology
 - most common cancer in women (excluding skin)
 - second leading cause of cancer mortality in women
 - most common cause of death in 5th decade
 - lifetime risk of 1/9
- etiology
 - multifactorial
 - genetics play key role in 15% of cases
- risk factors
 - age - 80% > 40
 - sex - 99% female
 - 1st degree relative with breast cancer
 - risk increased further if relative was premenopausal
 - geographic - highest national mortality in England and Wales, lowest in Japan
 - nulliparity
 - late age at first pregnancy
 - menarche < 12; menopause > 55
 - obesity
 - excessive alcohol intake
 - some forms of mammary dysplasia
 - prior history of breast cancer
 - history of low-dose irradiation
 - prior breast biopsy regardless of pathology
 - BCP/estrogen replacement may increase risk
- diagnostic workup of breast mass
 - history
 - how long the lump has been noted
 - any changes that have been observed
 - history of biopsy or breast cancer
 - breast CA risk factors should be noted, but their presence or absence do not influence decision to further investigate breast lump
 - physical
 - to identify those features that distinguish malignant from benign lump
 - benign: smooth, well-demarcated, mobile
 - malignant: irregular, poorly defined, less mobile
 - other signs of malignancy
 - skin changes: edema, dimpling, retraction, redness, ulceration
 - nipple: bloody discharge, crusting, ulceration, inversion
 - prominent veins, palpable axillary/supraclavicular lymph nodes, arm edema

- mammogram
 - stellate appearance and spiculated border - pathognomonic of breast cancer
 - microcalcifications
 - ill-defined lesion border
 - lobulation
 - architectural distortion
 - increased vascularity
 - interval mammographic changes
 - NORMAL MAMMOGRAM DOES NOT RULE OUT SUSPICION OF CANCER (BASED ON CLINICAL FINDINGS)
 - Fine Needle Aspiration
 - if non-bloody fluid and mass completely disappears, diagnosis is simple cyst - no need for cytology
 - if bloody/no fluid or mass does not fully disappear - send cells for cytology
 - biopsy
 - whenever reasonable doubt remains as to whether a lump is benign or malignant
 - core biopsy - removal of core of intact tissue through 14-gauge needle
 - excisional biopsy - surgical removal of entire lesion with cuff of normal tissue
- staging
- clinical vs. pathological
 - clinical: assess tumour size, nodal involvement, and metastasis
 - tumour size by palpation, mammogram
 - nodal involvement by palpation
 - metastasis by physical exam, CXR, LFTs
 - pathological
 - histology
 - axillary dissection should be performed for accurate staging and to reduce risk of axillary recurrence
 - estrogen/progesterone receptor testing

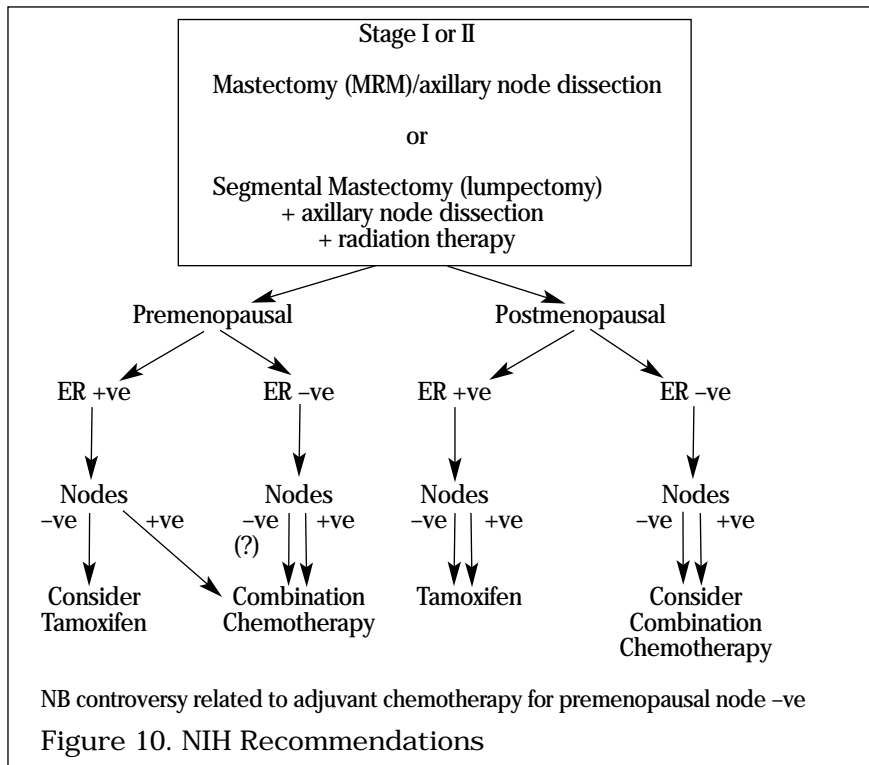
Stage	Tumour	Nodes (regional)	Metastasis
0	in situ	none	none
I	< 2 cm	none	none
II	< 2 cm or 2-5 cm	movable ipsilateral none or movable ipsilateral	none none
III	or > 5 cm any size or skin/chest wall invasion	none fixed ipsilateral or internal mammary any	none none none
IV	any tumour	any	distant

- pathology
- non-invasive
 - ductal carcinoma in situ
 - risk of development of infiltrating ductal carcinoma in same breast
 - excision with clear margins +/- radiation
 - lobular carcinoma in situ
 - risk marker for future infiltrating ductal carcinoma in either breast (20 to 30 % twenty year risk)
 - close follow-up (consider bilateral mastectomy for high-risk patient)
 - invasive
 - infiltrating ductal carcinoma (most common - 80%)
 - characteristics - hard, scirrhous, infiltrating tentacles, gritty on cross-section
 - invasive lobular carcinoma (8-10%)
 - more apt to be bilateral, better prognosis
 - Paget's disease (1-3%)
 - ductal carcinoma that invades nipple with scaling, eczematoid lesion
 - inflammatory carcinoma (1-4%)
 - ductal carcinoma that involves dermal lymphatics
 - most aggressive form of breast cancer
 - peau d'orange indicates advanced disease (IIIb-IV)
 - also papillary, medullary, colloid, tubular cancers

- sarcomas of breast (rare)
 - most common = giant benign variant of fibroadenoma (cystosarcoma phyllodes) - 1 in 10 malignant

Primary Treatment of Breast Cancer

- stages I, II - surgery for cure
 - Breast Conserving Surgery (lumpectomy)
 - removal of tumour along with cuff of normal tissue, preserving cosmetic appearance of breast
 - adjuvant radiation to breast decreases local recurrence (no change in survival)
 - results generally equal to mastectomy
 - mastectomy
 - removal of entire breast including nipple and fascia overlying pectoralis muscles, while sparing underlying muscles and innervation
 - indications
 - factors that increase risk of local recurrence: extensive calcification on mammogram, multiple tumours, or failure to obtain tumour-free margin
 - contraindications to radiation therapy: pregnancy, previous irradiation, collagen vascular disease, physical disability precluding treatment
 - large tumour size relative to breast
 - patient preference (no need for radiation)
 - see figure 10
- stages III, IV - operate for local control
- induction chemotherapy
 - tumours > 5 cm
 - inflammatory carcinomas
 - chest wall or skin extension



Adjuvant Therapy - Chemotherapy

- indications
 - sub-groups of stage I at high risk of recurrence
 - lymphatic invasion
 - high-grade tumours
 - high S-phase fraction
 - aneuploid DNA
- pre-menopausal patients tend to have better response to cytotoxic chemotherapy because of tendency for more aggressive tumours

- treatment
 - postmenopausal patients with positive lymph nodes, negative estrogen receptors
 - CMF x 6 months

Adjuvant Therapy - Hormonal

- estrogen and progesterone receptors
 - helps predict likelihood of regression when treated with hormonal therapy
 - prognostic significance
- most common adjuvant therapy = Tamoxifen (anti-estrogen)
- secondary treatments
 - previous clinical response to one hormonal treatment predicts response to another, thus secondary hormonal therapies are instituted
 - progestins - megestrol acetate (Megace)
 - aromatase inhibitors - induce medical adrenalectomy e.g. amino-glutethamide + hydrocortisone
 - estrogens - diethylstilbestrol
 - androgens - fluoxymesterone
 - oophorectomy - premenopausal patients with metastatic disease no benefit over tamoxifen

Adjuvant Therapy - Radiation

- with breast-conserving surgery
- those with high-risk of local recurrence
- adjuvant radiation to breast decreases local recurrence, increases disease free survival (no change in overall survival)

Post-Surgical Breast Cancer

- follow-up of post-mastectomy patient
 - history and physical every 4-6 months
 - yearly mammogram of remaining breast
- follow-up of segmental mastectomy patient
 - history and physical every 4-6 months
 - mammograms every 6 months x 2 years, then yearly thereafter
- when clinically indicated
 - chest x-ray
 - bone scan
 - LFTs
 - CT of abdomen
 - CT of brain

Local-Regional Recurrence

- recurrence in treated breast or ipsilateral axilla; 10% develop contralateral malignancy
- 50% have metastatic disease - need metastatic workup; occurs most frequently in first 3 years
- complete surgical excision or radiation therapy or both
- treatment is palliative for this group

Metastatic Disease

- lung 65%
- bone 56%
- liver 56%

Screening

- importance of early detection
- breast self exam, start age 20
- mammography > 50 years every 1-2 years or every year if high risk

Prognosis

- all patients: 63% 5 year survival, 46% 10 year survival
- most reliably determined by stage
- if disease localized to breast: 75-90% clinical cure rate
- if localized and receptor-positive: 90% 5-year survival
- if positive axillary nodes: 40-50% 5-year survival, 25% 10-year survival

MALE BREAST LUMPS

- gynecomastia
- breast carcinoma
 - usually > 50 years
 - hard, painless lump +/- nipple retraction, discharge, ulceration
 - often metastatic at time of diagnosis, therefore, poor prognosis

THYROID

(see Otolaryngology/Endocrinology Notes)

VASCULAR - ARTERIAL DISEASES**ARTERIAL INSUFFICIENCY**

- general overview
 - major risk factors
 - smoking
 - hypertension
 - hypercholesterolemia
 - minor risk factors: diabetes, hypertriglyceridemia, obesity, sedentary life style, family history
 - predominantly lower extremities
 - femoropopliteal system more common than aortoiliac
 - tandem lesions often present

CHRONIC ISCHEMIA

- predominantly due to atherosclerosis
- 80% improve or remain unchanged with conservative treatment, 5% develop gangrene
- signs and symptoms
 - claudication: 3 components
 - 1) discomfort with exertion - usually in calves
 - 2) relieved by rest - 5 to 10 minute rest
 - 3) reproducible - "claudication distance"
 - pulses: may be absent at some locations (document all pulses)
 - signs of poor perfusion: hair loss, deformed nails, atrophic skin, ulcerations and infections
 - other manifestations of atherosclerosis; CVD, CAD
- differential diagnosis
 - spinal stenosis
 - disc disease
 - arthritis
 - venous disease
- investigations
 - hand-held Doppler to confirm, assess and quantify pressures
 - ankle-brachial index: ABI = ankle systolic pressure divided by the arm systolic pressure
 - ABI > 1 normal; ABI < 0.5 rest pain;
 - ABI < 0.3 injuries usually cannot heal
 - angiogram = gold standard
- treatment
 - conservative
 - 90% of claudicants treated conservatively improve
 - decrease risk factors: stop smoking, manage diabetes and hypertension, lose weight, lower fat intake
 - exercise program to train muscles and develop collateral circulation
 - foot care (especially in diabetes)
 - cleanse between toes, cut nails carefully, treat sore/infection promptly

- surgical
 - consider if subjective disability is severe, i.e. walk < 1 block
 - see below for surgical options

CRITICAL ISCHEMIA

- ❑ arterial compromise eventually leading to necrosis
- ❑ signs and symptoms
 - rest pain, night pain in legs relieved by hanging feet over side of bed
 - ulcerations, gangrene of toes
 - pallor on elevation, dependent rubor, slow capillary refill
 - decreased or absent pulses
 - significant bruits may be heard (at 50% occlusion) - if stenosis severe, no bruit will be heard
 - ABI < 0.5
- ❑ investigations
 - as above
- ❑ treatment
 - needs immediate surgery due to risk of limb loss
 - initial procedures: transluminal angioplasty, laser, atherectomy and stents
 - operations include
 - inflow procedures for aortoiliac disease
 - endarterectomy
 - reconstructive procedures for superficial femoral artery occlusion
 - profundoplasty
 - femoropopliteal bypass
 - aortoiliac or aortofemoral bypass
 - axillofemoral bypass (uncommon)

ACUTE LIMB ISCHEMIA

- ❑ time is of the essence: after 6 hours, ischemia and myonecrosis irreversible
- ❑ emboli
 - etiology
 - cardiac source - most common; mural thrombus from previous MI, atrial fibrillation, rheumatic heart disease, mitral stenosis, cardiomyopathy, endocarditis, atrial myxoma
 - arterial source - proximal arterial source such as aneurysm, atheroembolism
 - paradoxical embolism - venous embolus passing through intracardiac shunt
 - presentation
 - sudden onset
 - no past history of claudication
 - pulses often present in contralateral limb
 - may have emboli to other locations i.e. head, arm, kidney
- ❑ arterial thrombosis
 - etiology
 - atherosclerosis, congenital anomaly, infection, hematologic disorders, low flow states e.g. CHF
 - presentation
 - develops over a few days with gradual progression of symptoms
 - past history of claudication
 - atrophic changes obvious
 - no contralateral pulses usually noted
- ❑ others
 - arterial trauma, drug-induced vasospasm (illicit drug use), aortic dissection, severe venous thrombophlebitis, prolonged immobilization, idiopathic
- ❑ physical examination and investigations
 - cardiac exam including complete bilateral pulse examination
 - 6 "P's" of acute arterial insufficiency
 - pain, pallor, pulseless, paresthesia, paralysis, polar (cold)

- atrophic skin and nail changes - longstanding arterial insufficiency
- CXR, ECG, arteriography
- management
 - immediate heparinization in all cases
 - thrombus
 - plan bypass with angiogram, bypass occlusion
 - embolus: embolectomy
 - surgical
 - Fogarty catheter
 - repeat angiography
 - identify and treat underlying cause
 - continue heparin post-op, start warfarin post-op day 3
 - reperfusion phenomenon
 - toxic metabolites from ischemic muscle → renal failure and multiorgan system failure
 - beware compartment syndrome with prolonged ischemia; requires fasciotomy
 - treatment of irreversible ischemia is amputation

ABDOMINAL AORTIC ANEURYSM

- aneurysm = a permanent increase in arterial diameter > 50% of normal artery
- AAAs most commonly infrarenal
- incidence = 1.8-6.6%
- frequently associated with other peripheral aneurysms

Etiology

- > 95% due to atherosclerosis
- others - trauma, infection, connective tissue disease
- high risk groups
 - > 65 years old
 - male:female = 3.8:1
 - peripheral vascular disease, CAD, CVD
 - family history AAA

Clinical Presentation

- 75% asymptomatic (often discovered incidentally)
- symptoms due to acute expansion or disruption of wall
 - syncope, pain (abdominal, flank, back)
- partial bowel obstruction
- duodenal mucosal hemorrhage → GI bleed
- erosion of aortic and duodenal walls → aortoduodenal fistula
- erosion into IVC → aortocaval fistula
- distal embolization
- signs
 - hypotension
 - palpable mass felt at/above umbilicus
 - bounding femoral pulses
 - distal pulses may be intact
- investigations
 - U/S (confirm AAA with initially)
 - CT (accurate visualization)

Treatment and Prognosis

- indication for operation is to prevent rupture
- risk of rupture depends on
 - size
 - 4-5 cm - 5%
 - 5-6 cm - 20%
 - > 6 cm-50%
 - rate of growth (> 0.4 cm/yr)
 - presence of symptoms, hypertension, COPD
- operate at 5-6 cm since risk of rupture > risk of surgery
 - mortality of elective repair = 3-5% (mostly due to MI)
- consider revascularization for patients with CAD before elective repair

RUPTURED ABDOMINAL AORTIC ANEURYSM

- 100% mortality if untreated
- diagnosis must be made by history and physical
- signs and symptoms
 - classic triad - abdominal pain, pulsatile abdominal mass, syncope
 - nearly pathognomonic for RAAA
 - sudden collapse
 - shock, peripheral vasoconstriction, hypotension, anuria
 - retroperitoneal RAAA may not cause hypotension or triad
 - ECG confusing
 - may show cardiac ischemia
- if patient stable without classic triad → consider CT
- do not waste time in radiology if RAAA strongly suspected
- treatment
 - initial resuscitation including vascular access, notify OR, ensure availability of blood products, invasive monitoring
- prognosis
 - 45% survival for patients who make it to OR

AORTIC DISSECTION

- usually in thoracic aorta
- pathogenesis
 - starts with intimal tear → entry of blood separates media → false lumen created → dissection often continues to aortic bifurcation
- male:female = 3-4:1
- predominantly older patients
- etiologic factors
 - hypertension
 - cystic medial necrosis (not atherosclerosis)
- associated factors
 - Marfan's Syndrome
 - coarctation of aorta
 - congenital bicuspid aortic valve
- clinical manifestations
 - sudden searing chest pain that radiates to back
 - branch vessel "sheared off" leading to various ischemic syndromes
 - MI with proximal extension to coronary arteries
 - "unseating" of aortic valve cusps
 - new diastolic murmur in 20-30%
 - asymmetric BPs and pulses between arms
 - neurologic injury - stroke (10%) and spinal cord (paraplegia 3-5%)
 - renal insufficiency
 - lower limb ischemia
 - cardiac tamponade with rupture of false lumen into pericardium
 - 75-85% of patients hypertensive
- diagnosis and investigations
 - CXR
 - pleural cap
 - widened mediastinum
 - left pleural effusion with extravasation of blood
 - ECG
 - most common abnormality is LVH (90%)
 - transesophageal echocardiography
 - CT
 - aortography
- treatment
 - immediate drug therapy to lower BP and decrease cardiac contractility
 - usually sodium nitroprusside and β-blocker
 - ascending aortic dissections operated on emergently
 - descending aortic dissections initially managed medically
 - 10-20% require urgent operation for complications

DEEP VEIN THROMBOSIS

- pathogenesis
 - Virchow's Triad - stasis, hypercoagulability, endothelial damage
- risk factors
 - stasis
 - surgery
 - trauma and subsequent immobilization
 - immobilization due to: acute MI, stroke, CHF
 - hypercoagulability
 - pregnancy
 - estrogen use
 - neoplasms: diagnosed, occult, undergoing chemotherapy
 - tissue trauma: activation of coagulation
 - nephrotic syndrome
 - deficiency of anti-thrombin III, protein C or S
 - endothelial damage: venulitis, trauma
- clinical presentation
 - most frequent site of thrombus formation is calf
 - isolated calf thrombi often asymptomatic
 - 30-50% are asymptomatic or minimal symptoms
 - 20-30% extend proximally and account for most clinically significant emboli
 - classic presentation < 1/3
 - calf or thigh discomfort
 - edema
 - venous distension
- complications
 - varicose veins
 - chronic venous insufficiency
 - pulmonary embolus
 - venous gangrene
 - phlegmasia cerulea dolens (PCD) - massive DVT with clot extension to iliofemoral system and massive venous obstruction resulting in a cyanotic, immensely swollen, extremely painful and critically ischemic leg
 - risk venous gangrene
 - phlegmasia alba dolens (PAD) - as above with additional reflex arterial spasm resulting in less swelling than PCD
 - cool leg and decreased pulses
- diagnosis (refer to PLOPED study for details)
 - history and physical
 - calf tenderness (if elicited on ankle dorsiflexion = Homan's sign)
 - wider circumference of affected leg
 - fever POD 7-10
 - clinical assessment incorrect 50% time, therefore must confirm by objective method
 - non-invasive tests
 - duplex doppler U/S
 - 93% sensitive and 98% specific for symptomatic patients, decreased for asymptomatic patients
 - detects proximal thrombi
 - initial negative exam should be repeated 6-7 days later to detect proximal extension
 - invasive testing
 - ascending phlebography (venogram)
 - the gold standard but costly
 - detects distal and proximal thrombi
 - complicated by contrast-induced thrombosis of peripheral veins (2-3%)
- treatment
 - goals of treatment
 - prevent formation of additional thrombi
 - inhibit propagation of existing thrombi
 - minimize damage to venous valves
 - prevent pulmonary emboli
 - 25% develop PE if untreated; 5% if treated

- conservative
 - bed rest with limb elevation for 1-3 days
 - medical
 - IV heparin, 5000 U bolus + 1000 U/hr to keep aPTT 2-2.5x control
 - convert to warfarin 3-7 days after full heparinization
 - 3-6 months of prophylactic warfarin against recurrence
 - risks of therapy - bleeding, heparin-induced thrombocytopenia, warfarin is teratogenic
 - surgical
 - venous thrombectomy - if arterial insufficiency with extensive iliofemoral thrombosis, +/- venous gangrene
 - IVC (Greenfield) filter- inserted percutaneously
 - indications
 - recurrent PE despite anticoagulation
 - contraindication to anticoagulation e.g. intra-cranial trauma
 - certain operations for cancer, pulmonary embolism
 - septic emboli refractory to combination antibiotic and anticoagulation
 - "free-floating" thrombus loosely adherent to wall of IVC or pelvic veins
 - IVC ligation, surgical clips - increases risk of venous insufficiency; rarely used
- DVT prophylaxis
- conservative
 - minimize risk factors
 - early ambulation, passive range of motion
 - anti-embolism stockings
 - pneumatic sequential compression devices
 - elevation of limb
 - medical prophylaxis
 - optimize hydration
 - ECASA, dextran, warfarin, minidose heparin (5,000 U SC q8-12h) in high risk situations

VARICOSE VEINS

- saccular dilatations and elongation of superficial veins of leg
- can also occur in
 - esophagus - esophageal varices
 - anorectum - hemorrhoids
 - scrotum - varicocele
- etiology
 - primary
 - most common form of venous disorder of lower extremity
 - affects 10-20% of population
 - inherited structural weakness of vein wall is main factor
 - contributing factors
 - age
 - female
 - BCP use
 - occupations requiring long hours of standing
 - pregnancy
 - obesity
 - secondary
 - result of increased venous pressure from
 - deep-venous valvular insufficiency and incompetent perforating veins
 - malignant pelvic tumours with venous compression
 - congenital anomalies
 - acquired/congenital arteriovenous fistulae

- ❑ clinical manifestations
 - greater saphenous vein is most frequently involved with dilated tributaries
 - diffuse aching, fullness or tightness, occasional nocturnal cramping
 - aggravated by prolonged standing, end of day, prior to menses
 - relieved by elevation of leg, elastic stockings
- ❑ complications
 - recurrent superficial thrombophlebitis
 - hemorrhage - externally or into subcutaneous tissues
 - ulceration, eczema, lipodermatosclerosis, hyperpigmentation
- ❑ physical exam
 - patient standing: long, dilated and tortuous superficial veins along thigh and leg
 - if ulceration, hyperpigmentation, indurated appearance think secondary varicose veins
 - Brodie-Trendelenberg test (valvular competence test)
 - while patient is supine, raise leg and compress saphenous vein at thigh; have patient stand; if veins fill quickly from top down then incompetent valves; normally gradual fill from bottom up; do test with multiple tourniquets to localize incompetent communicating veins
- ❑ treatment
 - primary indication is usually cosmetic
 - surgery for failure of conservative management or complications
 - non-operative
 - leg elevation
 - graduated compression stockings
 - operative
 - high ligation of saphenofemoral junction and stripping of greater saphenous vein
 - sclerotherapy-not favored
- ❑ prognosis
 - natural history benign, slow with unpredictable complications
 - almost 100% symptomatic relief if varicosities are primary
 - generally good cosmetic results
 - 10% post-operative recurrence

SUPERFICIAL THROMBOPHLEBITIS

- ❑ a combination of thrombosis and phlebitis occurring in any superficial vein in the body
- ❑ clinical manifestations
 - pain and cord-like swelling along course of involved vein; most commonly involves long saphenous vein
 - non-invasive tests e.g. duplex doppler U/S to exclude presence of associated DVT (5-10%)
- ❑ etiology
 - trauma
 - association with varicose veins
 - migratory superficial thrombophlebitis
 - Buerger's disease
 - SLE
 - polycythemia
 - thrombocytosis
 - occult malignancy (especially pancreas)
 - idiopathic
- ❑ treatment
 - conservative
 - moist heat, compression bandages, mild analgesics (e.g. ASA), ambulation
 - surgical - for failure of conservative measures; excise involved vein
 - if suppurative thrombophlebitis - IV antibiotics and excise involved vein

CHRONIC DEEP VEIN INSUFFICIENCY

- post-phlebitic syndrome
- late complication of DVT
- recanalization of thrombosed veins with resulting damaged incompetent valves
- impairment of calf muscle "pump"
- sustained venous hypertension
- onset is weeks to years after initial thrombosis
- clinical manifestations
 - most common symptom is pain; relieved on recumbency and foot elevation
 - aching fullness of leg, edema
 - pigmentation - hemosiderin deposits
 - varicose veins
 - venous dermatitis
 - ulcers above medial malleolus
 - positive Brodie-Trendelenberg
- diagnostic tests
 - gold standard is ambulatory venous pressure measurement
 - rarely done
 - doppler U/S
 - photoplethysmography
- treatment
 - non-operative
 - elastic compression stockings, leg elevation, avoid prolonged sitting/standing
 - ulcers treated with zinc-oxide wraps (unna boot), split-thickness skin grafts, antibiotics, debridement
 - operative
 - consider after failure of conservative measures, recurrent or very large ulcerations
 - surgical ligation of perforators in region of ulcer, strip greater saphenous vein

HIV AND GENERAL SURGERY

GI Manifestations

- common pathogens
 - Cytomegalovirus
 - *Mycobacterium avium intracellulare* (MAI)
 - *Cryptosporidium*
 - *Microsporidia*
 - *Isospora belli*

SUSCEPTIBLE ORGANS IN GI TRACT

- oropharynx
 - Kaposi's sarcoma causing dysphagia, obstruction, bleeding
- esophagus
 - esophagitis +/- dysphagia secondary to *C. albicans*, CMV or Herpes
 - surgery only if perforation occurs
- stomach and small bowel
 - abdominal pain
 - antral obstruction
 - pain
 - duodenitis with ulceration +/- perforation and bleeding
- liver and biliary tract
 - hepatitis secondary to CMV, MAI or *P. carinii*
 - sclerosing cholangitis-like syndrome secondary to CMV and *Cryptosporidium*
 - cholangitis/cholecystitis secondary to obstruction by Kaposi's or lymphoma
 - acalculous cholecystitis
- pancreas
 - rarely involved
 - pancreatitis secondary to HIV therapies (e.g. dideoxynucleosides)
- appendix
 - can present with very confusing picture - often not diagnosed until perforated

- cannot rely on increased WBCs
- morbidity of negative appendectomy high
- colon
 - colitis (intractable diarrhea, weight loss, fever, melena, hematochezia) secondary to CMV
 - perforation and massive bleeding can occur requiring segmental resection with colostomy
 - watery diarrhea, dehydration, malabsorption, pain secondary to MAI - may cause perforation, obstruction, fistula
- anorectum
 - condyloma acuminata (secondary to HPV) - malignant transformation to squamous carcinoma has been reported
 - fistula
 - anorectal ulcers
 - non-Hodgkin's lymphoma
 - Kaposi's sarcoma
- remember that just because a patient has HIV does not mean they can't have GI pathology unrelated to HIV

UNUSUAL MALIGNANCIES

Kaposi's Sarcoma of GI Tract

- clinical presentation
 - dysphagia, protein losing enteropathy, abdominal pain, diarrhea, tenesmus, obstruction, bleeding, perforation
 - may be asymptomatic
- diagnosis
 - endoscopy and deep biopsies
- surgical treatment
 - indicated for life-threatening situations, or for severe complaints
 - never curative

Lymphoma

- tend to be aggressive
- rarely surgical
- good response to chemotherapy
- high recurrence rate

INDICATIONS FOR SURGERY IN HIV+ PATIENTS

- diagnostic procedures
 - CD4+ < 200/mm³ diagnostic of AIDS
 - fewer procedures required to diagnose opportunistic infections and tumours (Kaposi's)
 - lymphadenopathy may require diagnostic procedures such as biopsy
 - biopsy recommended on patients with single node or group of nodes that are enlarged out of proportion to other nodes, especially when systemic symptoms (fever, weight loss) are also present
- supportive surgical measures
 - tracheostomies and long term IV access devices
 - no studies on morbidity and mortality rates on these indications
- emergency surgery
 - acute abdomen may be secondary to AIDS or independent of disease
 - infectious diagnosis rarely associated with peritoneal findings
 - bowel obstruction in HIV+ or AIDS patient most often secondary to HIV-associated problems (intestinal lymphoma, Kaposi's)
 - GI perforation secondary to CMV leading to emergency surgery has 30 day mortality rate of 50-70%; high rates usually secondary to underlying illness; if survive, morbidity high; 31% wound dehiscence rate in all intra-abdominal sepsis cases
 - poor outcome from emergency surgery is combination of hypoalbuminemia and known opportunistic infection

NOSOCOMIAL TRANSMISSION

- 0.3% transmission rate of HIV from patient to health care worker
- Florida dentist case remains only instance in which transmission from infected health care worker to patient has been documented
- prevention through: HIV testing of patients +/- doctors (but costs high), nonoperative management and universal precautions

- rapidly evolving
- ethical, legal, social issues important
- genetic counseling mandatory
- most DNA testing still within research protocols

Table 10. Cancer Genes in Clinical/Research Testing

Gene	Syndrome
APC	Familial adenomatous polyposis (FAP)
MSH2, MLHI, PMSI, PMS2	Hereditary non-polyposis colorectal cancer (HNPCC)
BRCA1	Hereditary breast/ovarian cancer
BRCA2	Hereditary breast cancer/male breast cancer
p53	Li-Fraumeni syndrome
ATM	Ataxia-telangiectasia (increased breast cancer risk)
OPC4	Juvenile Polyposis